

The Equine Practitioner



DISEASES OF THE PHARYNX

C. W. Raker, VMD
University of Pennsylvania
New Bolton Center
Kennett Square, Pennsylvania 19348

PHARYNGEAL LYMPHOID HYPERPLASIA

Pharyngeal lymphoid hyperplasia (chronic pharyngitis) is the most common cause of upper airway obstruction or respiratory embarrassment. It occurs most frequently in horses under 3 years of age, with practically all viral or bacterial respiratory diseases. Many owners and trainers believe a horse has recovered when the cough, fever, or nasal exudate disappears. In many of these horses, however, endoscopy at this time reveals inflammation and varying degrees of follicular pharyngitis.

Young horses commonly have small follicles filled with lymphoid tissue scattered over the dorsal pharyngeal mucosa. At 2 or 3 years the size and number of follicles may decrease, and horses 4 to 5 years of age have only a few. Horses with active follicular pharyngitis have large, numerous follicles covering the dorsal wall of the pharynx and often extending to or below the level of the guttural pouch openings. Many follicles are glistening red and appear edematous, suggesting an acute inflammatory reaction; others appear firm, white, and fibrotic, suggesting a chronic situation. Large follicles often appear pedunculated.

The more extensive (number and size) the lymphoid follicular change the more apt the horse is to experience respiratory distress. The inflammatory lesion decreases airway size, thus increasing negative pressure during inspiration, which results in the dorsal wall of the pharynx being pulled down and the soft palate elevated. Additional airway restriction may occur if the

horse is tense or "swallows his tongue," as pulling the tongue back into the oral cavity elevates the soft palate. Also, a horse "on the bit"—who wants to go on but is restrained by the rider—will carry the head in a flexed position, which further decreases airway size. With restricted flow of air, the increased resistance and turbulence may mechanically irritate the mucosa.

In acute lymphoid hyperplasia, biopsies reveal masses or aggregates of lymphocytes; in more chronic cases the aggregates are less dense, and there is more fibrosis. Cultures have not been particularly rewarding, a great variety of organisms having been found.

Treatment

Prolonged rest often results in sufficient regression of signs to allow the horse to train and race successfully. Sprays consisting of DMSO, Furacin solution, and prednisolone applied once or twice daily to the pharyngeal mucosa, through a nasal tube, may be of some benefit, as may systemic administration of large doses of corticosteroids and antibiotics. However, it has been difficult to conduct controlled studies, and the information available is based on clinical evaluation.

A plastic insemination pipette, with 1 end heat-sealed and 6 or more small holes placed around its periphery, has been satisfactory for administering medication to the nasopharyngeal mucosa. With a short length of rubber tubing and Luer-lock adapter attached to the opposite open end, 10-15 ml of medication is delivered through a syringe. Adequate restraint is required to prevent the horse from throwing its head and breaking the tube. Other more flexible plastic or polyethylene tubes may be used in a similar fashion.

Page 397 is a full page advertisement and has been removed.

Page 398 is a full page advertisement and has been removed.

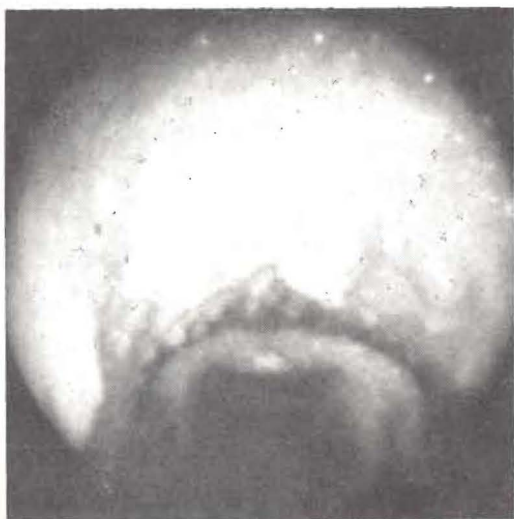

Fig 1. Grade IV lymphoid hyperplasia. Note the size and large number of lymphoid follicles protruding from the dorsal pharyngeal wall.

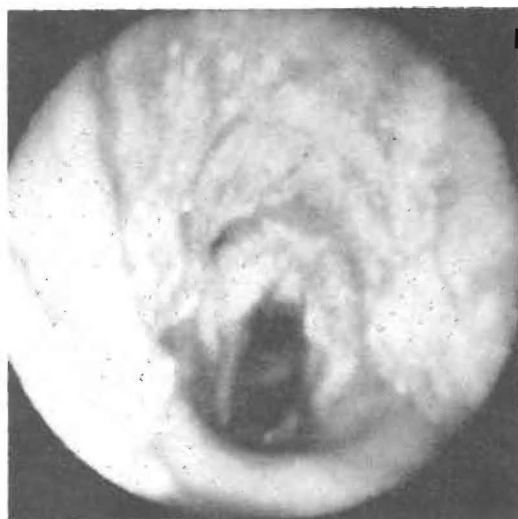


Fig 2. The appearance of the pharyngeal mucosa 1 day following cauterization.

Several chemical agents have been used to cauterize the nasopharyngeal mucosa, with limited to negative results, and about 2 years ago electrocautery was initiated. The procedure has been performed under general anesthesia in the dorsal recumbent position, through a standard laryngotomy approach. If necessary to obtain increased working space, the body of the thyroid cartilage is severed. Using a Bovie electro-surgical unit with a long ball-tip applicator at a setting of "55" the entire mucosa on the dorsal surface and walls of the pharynx is cauterized to a light tan or copper color. Overzealous application may result in excess scar tissue formation. The arytenoid cartilages should be retracted as required to protect them from being cauterized.

The swallowing reflex must be abolished (obtained in part by the general anesthesia) with a topical anesthetic drug. Preparation of the patient and aftercare are as described for standard laryngotomy. Every follicle adequately cauterized has regressed. Postoperative endoscopy is repeated once or more during the first week. A progress examination is conducted in 30-45 days at which time healing is nearly if not entirely complete. Training can usually be resumed in 45 days.

PHARYNGEAL CYSTS

Pharyngeal cysts are diagnosed more frequently in the Standardbred than the Thoroughbred, the most common location being

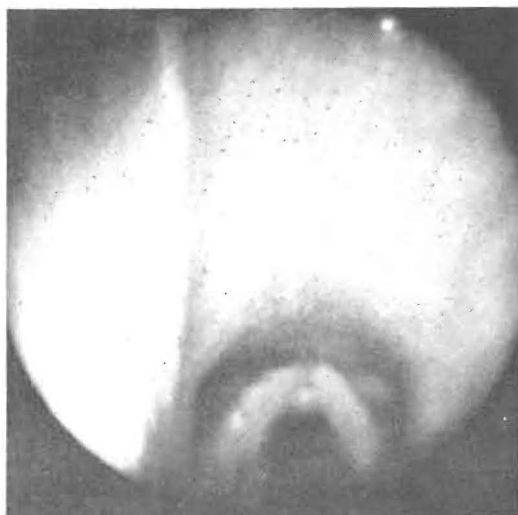


Fig 3. The appearance of the pharyngeal mucous membrane 60 days following cauterization for lymphoid hyperplasia.

beneath the epiglottis (subepiglottidal cyst) probably as an embryonic remnant of the thyroglossal duct. One cyst seen on the dorsal pharyngeal wall probably was a remnant of Rathke's pouch. Pharyngeal cysts probably represent a congenital defect, having been diagnosed in foals 1 day of age, but they are usually not brought to the veterinarian's attention until the animal is put into work or placed under stress.

The clinical signs are those of upper airway obstruction. A noise and respiratory distress are evident on both inspiration and expiration; at times the horse may appear to be "choking to death." It may be more

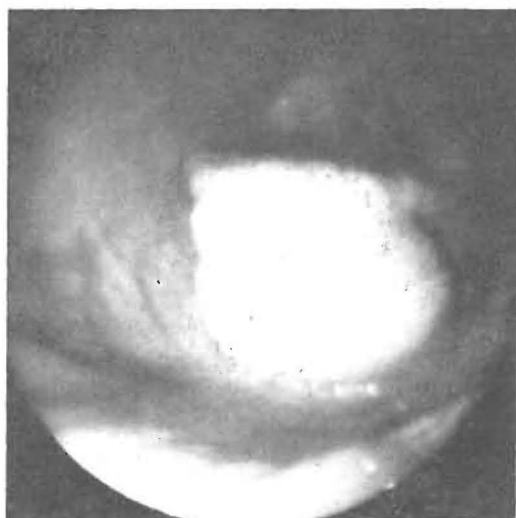


Fig 4. A large mucoïd cyst lies beneath the epiglottis, the common location for pharyngeal cysts.

difficult for the horse to swallow. Noise is usually evident only when the horse is worked or excited. Endoscopy is necessary to confirm the diagnosis.

Treatment

Effective treatment requires excision of the cyst. A surgical approach through the mouth can be tried but in general has proved unsatisfactory. Operation through the mouth has to be done by feel since there is not sufficient room for the hand and an endoscope. A snare is placed over the cyst, cutting it off.

The preferred approach is to place the horse under general anesthesia in dorsal recumbency. A laryngotomy is performed by incising the skin, separating the 2 sternothyrohyoideus muscles, and incising the cricothyroid membrane. The index finger is introduced into the larynx and passed forward over the body of the thyroid cartilage, where it will be in contact with the dorsal surface of the epiglottis.

By manipulation with the index finger, the epiglottis is everted into the larynx and through the incision; this can be facilitated by incising the body of the thyroid cartilage. The epiglottis is held in an everted position with a sponge forceps, thus exposing the cyst beneath it. The mucous membrane is incised and the cyst dissected from the depths of the tissue.

If the cyst is accidentally ruptured, efforts are made to seal it by clamping with a

hemostat; a collapsed cyst is difficult to remove. If the secretory lining is not removed the areas should be swabbed with a chemical debriding agent such as Lugol's iodine. Avoid spilling the iodine on adjacent delicate mucous membranes. Excess mucosa may be removed and the wound left to heal by granulation. If possible, apposing the mucosal edges with 00 gut sutures is preferred, and all ends of the suture material should be buried. Exposed suture material may result in a granulomatous reaction. The body of the thyroid cartilage is not sutured, and no complications (chondromas) have been observed. Sutures placed through the cartilage may even be contraindicated.

The laryngotomy incision may be left open to heal by granulation, or it can be partially closed, leaving a small central area for drainage. The cricothyroid membrane may or may not be sutured, but sutures should not be placed through the mucosa. The sternothyrohyoideus muscles are tacked together, and the skin edges are incompletely approximated. The operative field is no longer sterile, and a suitable drainage tube should be placed beneath the muscles next to the ventral surface of the larynx if the incision is completely closed. The ends should be brought through stab incisions made through the skin and securely anchored. The drain may be removed in 5 to 7 days or when no longer functioning.

The prognosis is favorable. The most serious complications are adhesions, which may restrict movement of the epiglottis.

The horse should be kept from work for about 30 days. The results of surgery and healing should be evaluated by endoscopy as required. Antibiotics, for 3 to 5 days after surgery, and tetanus antitoxins are indicated. An emergency tracheotomy set should be available at stall side for the first 24 hours. Seldom does sufficient airway obstruction develop to warrant the use of a tube. Giving 2 g phenylbutazone at the time of surgery appears to control the immediate inflammatory response. Difficulty in swallowing may be encountered for a few days, as indicated by presence of food at the external nares. These signs usually disappear within 72 hours. □

Based on a presentation at the Annual Conference for Veterinarians, Cornell University, January 1976.