

SPONSORED BY AN EDUCATIONAL GRANT FROM
BOEHRINGER INGELHEIM VETMEDICA, INC.

CLINICAL NOTES:

Canine heart failure—early diagnosis, prompt treatment

Early detection of clinical signs by the pet owner and selection of proper diagnostics and accurate interpretation of results by the veterinarian are important prerequisites for the treatment of heart failure in dogs. A commonly cited clinical definition of heart failure is exertional clinical signs caused by underlying heart disease.¹ Many cases of early congestive heart failure can be identified by owners if they have been trained by the veterinary staff to routinely monitor their pet's respiratory rate and effort. Early detection leads to prompt treatment, which in turn optimizes the time during which the pet can enjoy a healthier life.

In dogs, mitral valve disease (MVD) and dilated cardiomyopathy (DCM) are the most common causes of heart failure, with prevalence being very high in certain breeds (90% for MVD in older Cavalier King Charles spaniels,² 33%-50% for DCM in Doberman pinschers³). Heart failure typically manifests in signs of either congestion ("backward heart failure") or low cardiac output ("forward heart failure").

DIAGNOSIS OF HEART FAILURE

Diagnosis of heart failure involves careful history taking, physical examination, and in cases of left-sided failure, thoracic radiography (see **Radiographic Signs of Left-Sided Heart Failure**). Echocardiography, electrocardiography, and blood pressure measurement add to the diagnostic database but often are not required to achieve a working diagnosis and to formulate an initial treatment plan.

In dogs with underlying MVD, the history typically involves a chronic murmur, increased respiratory rate and effort, coughing, poor appetite, and/or activity intolerance. Sometimes the signs are very subtle, but in the typical case, they are both persistent and progressive. In contrast, in cases of primary airway or respiratory disease, signs are often intermittent and absent in the resting or sleeping pet. Dogs with DCM show these signs as well but have a higher incidence of low-output signs, such as exercise intolerance, weakness, or syncope episodes.

PHYSICAL EXAMINATION AND DIAGNOSTICS

In dogs with MVD or DCM, physical examination typically reveals a systolic heart murmur over the left apex. Heart rate is usually elevated and arrhythmias may be detected. Auscultation of the lung fields reveals increased bronchovesicular sounds or in some cases crackles. Pulmonary crackles are *not* specific to congestive heart failure; they are often detected in cases of primary lower airway or parenchymal disease.

In dogs with MVD, femoral pulse quality is usually normal, while those with DCM may have weak or thready pulses. In cases of tricuspid valve disease, advanced mitral valve disease with pulmonary hypertension, atrial fibrillation, or DCM, jugular vein distention or pulses can be detected.

When left-sided heart failure is suspected (pulmonary edema or pleural effusion), thoracic radiography is the diagnostic test of choice.

In the absence of any of these findings, a diagnosis of congestive heart failure is in doubt and the veterinarian should consider extracardiac (respiratory) causes. When the dog exhibits some or all of these signs, however, ameliorative intervention should be instituted without delay.



KEY POINTS

- Clinical signs of heart failure can be subtle.
- Thoracic radiography is invaluable in detecting left-sided heart failure.
- Consensus guidelines recommend "triple therapy" of furosemide, pimobendan, and an ACE inhibitor as first-line therapy in dogs with heart failure.
- Triple therapy along with spironolactone represents best practice for dogs with heart failure.
- Don't wait. Treatment at the first sign of heart failure offers the best opportunity for a longer, healthier life.

Radiographic Signs of Left-Sided Heart Failure

- Significant left-sided heart enlargement manifested as:
 - Increased vertebral heart size
 - Increased height of the cardiac silhouette/loss of the caudal cardiac waist on lateral projection
 - Left auricular enlargement at the 2- to 3-o'clock position on the dorsoventral or ventrodorsal projection
- Enlarged pulmonary veins
- Perihilar and/or caudodorsal interstitial or alveolar pattern

It is common to overestimate heart size, particularly in small-breed dogs with shallow chests.

TREATMENT OF HEART FAILURE

In 2009, the American College of Veterinary Internal Medicine (ACVIM) released an expert consensus statement outlining recommendations for treatment of heart failure in dogs with MVD.⁴ There are fewer clinical trials to help formulate consensus guidelines for DCM, but in general the recommendations for MVD apply.

Appropriate treatment of first-time heart failure in dogs with MVD should include furosemide, pimobendan, and an ACE inhibitor (see **Treatment Guidelines**). The route and dose of furosemide administration depend on the degree of respiratory distress and disability.

Experimental evidence and positive anecdotal experience by cardiology specialists indicate that pimobendan, a dual-acting vasodilator and positive inotrope, should also be administered acutely.⁴ ACE inhibitors are unlikely to substantially improve heart failure in the acute setting.

For home-based therapy in dogs recovering from acute heart failure or for initial therapy in dogs with milder heart failure, furosemide, pimobendan, and ACE inhibition with enalapril or benazepril should be employed. Monitoring renal function before and 3 to 5 days after initiation of furosemide and an ACE inhibitor is recommended.

Treatment Guidelines

Severe disability requiring hospitalization

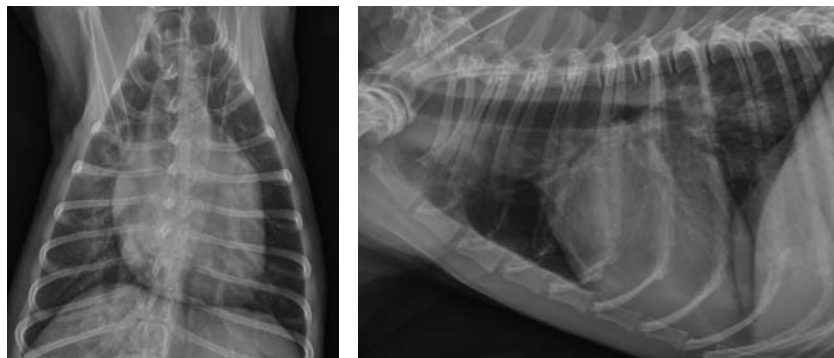
- **Furosemide:** Initial doses of 2–4 mg/kg IV, followed by doses Q 2–3 H as determined by respiratory effort and rate, urine production, renal function, and hydration
- **Pimobendan:** 0.25 mg/kg PO Q 12 H
- **ACE inhibitor:** Delay until dog ready for home-based care
- **Supplemental:** Oxygen, nitroglycerin paste, nitroprusside infusion, light sedation as needed to relieve anxiety

Home-based therapy (also for initial therapy of milder heart failure)

- **Furosemide:** 1–2 mg/kg PO Q 12 H
- **Pimobendan:** 0.25 mg/kg PO Q 12 H
- **ACE inhibitor:** 0.5 mg/kg PO Q 12 H enalapril or 0.25–0.5 mg/kg PO Q 24 H benazepril

Quadruple therapy (along with furosemide, pimobendan, ACE inhibitor)

- **Spironolactone:** 2 mg/kg PO Q 24 H; monitor renal function and electrolytes



Dorsoventral (DV) and right lateral thoracic radiographs of a 12-year-old Maltese dog with MVD and congestive heart failure. Note the left-sided heart enlargement, enlarged pulmonary veins, and perihilar and caudodorsal interstitial pattern.

For use as chronic therapy, each of these three agents is supported by either extensive clinical anecdotal experience (furosemide) or clinical trial data (pimobendan⁵ and ACE inhibitor^{6,7}).

In addition, 2010 data supported use of spironolactone in dogs with heart failure due to MVD, finding improved longevity and clinical outcome.⁸ Thus, spironolactone is now approved for use in dogs in Europe, and U.S. cardiologists are considering it a part of quadruple therapy in dogs with heart failure.

The incidence of ventricular arrhythmias and sudden death is higher in cases of DCM than in MVD, leading to greater use of antiarrhythmic medications. This aspect of treatment is beyond the scope of this article.

PROGNOSIS

Preservation of quality of life is of primary importance to dog owners.⁹ In dogs with heart failure, quality of life can be improved with prompt and continuous use of pimobendan, diuretics, and an ACE inhibitor. Despite a guarded long-term

prognosis, the pet can live a comfortable, high-quality life with early detection, accurate diagnosis, and immediate medical therapy.

REFERENCES

1. **Task force report. Guidelines for the diagnosis and treatment of chronic heart failure, European Society of Cardiology.** Remme WJ, Swedberg K (chairs). *Eur Heart J* 22:1527–1560, 2001.
2. **Canine degenerative myxomatous mitral valve disease: Natural history, clinical presentation and therapy.** Borgarelli M, Haggstrom J. *Vet Clin North Am Small Anim Pract* 40:651–663, 2010.
3. **Dilated cardiomyopathy: An update.** O'Grady MR, O'Sullivan ML. *Vet Clin North Am Small Anim Pract* 34:1187–1207, 2004.
4. **Guidelines for the diagnosis and treatment of canine chronic valvular heart disease.** Atkins C, Bonagura J, Ettinger S, et al. *J Vet Intern Med* 23:1142–1150, 2009.
5. **Effect of pimobendan or benazepril hydrochloride on survival times in dogs with congestive heart failure caused by naturally occurring myxomatous mitral valve disease: The QUEST study.** Haggstrom J, Boswood A, O'Grady M, et al. *J Vet Intern Med* 22:1124–1135, 2008.
6. **Effects of enalapril maleate on survival of dogs with naturally acquired heart failure.** The Long-Term Investigation of Veterinary Enalapril (LIVE) Study Group. Ettinger SJ, Benitz AM, Ericsson GF, et al. *JAVMA* 213:1573–1577, 1998.
7. **The effect of benazepril on survival times and clinical signs of dogs with congestive heart failure: Results of a multicenter, prospective, randomized, double-blinded, placebo-controlled, long-term clinical trial.** The BENCH Study Group. *J Vet Cardiol* 1:7–18, 1999.
8. **Efficacy of spironolactone on survival in dogs with naturally occurring mitral regurgitation caused by myxomatous mitral valve disease.** Bernay F, Bland JM, Haggstrom J, et al. *J Vet Intern Med* 24:331–341, 2010.
9. **Perceptions and priorities of owners of dogs with heart disease regarding quality versus quantity of life for their pets.** Oyama MA, Rush JE, O'Sullivan ML, et al. *JAVMA* 233:104–108, 2008.



Mark A. Oyama, DVM, Diplomate ACVIM (Cardiology)
University of Pennsylvania School of Veterinary Medicine

The opinions expressed herein do not necessarily reflect the point of view of the publisher or sponsor.

