



9-2012

Canine Multifocal Retinopathy in the Australian Shepherd: A Case Report

Ingo Hoffmann

Karina E. Guziewicz

University of Pennsylvania, karinag@vet.upenn.edu

Barbara Zangerl


University of Pennsylvania, bzangerl@vet.upenn.edu

Gustavo D. Aguirre

University of Pennsylvania, gda@vet.upenn.edu

Christian Y. Mardin

Follow this and additional works at: https://repository.upenn.edu/vet_papers

 Part of the [Animal Diseases Commons](#), [Congenital, Hereditary, and Neonatal Diseases and Abnormalities Commons](#), [Eye Diseases Commons](#), [Medical Genetics Commons](#), [Medical Immunology Commons](#), [Ophthalmology Commons](#), and the [Veterinary Medicine Commons](#)

Recommended Citation

Hoffmann, I., Guziewicz, K. E., Zangerl, B., Aguirre, G. D., & Mardin, C. Y. (2012). Canine Multifocal Retinopathy in the Australian Shepherd: A Case Report. *Veterinary Ophthalmology*, 15 (Issue Supplement s2), 134-138. <http://dx.doi.org/10.1111/j.1463-5224.2012.01005.x>

Canine Multifocal Retinopathy in the Australian Shepherd: A Case Report

Abstract

A 1-year-old Australian Shepherd (AS) was presented for a routine hereditary eye examination. During the examination multiple raised, brown to orange lesions were noted in the fundus, which could not be attributed to a known retinal disease in this breed. As they clinically most closely resembled canine multifocal retinopathy (*cmr*) and no indication of an acquired condition was found, genetic tests for *BEST1* gene mutations were performed. These showed the dog to be homozygous for the *cmr1* (C73T/R25X) gene defect. Furthermore, ultrasound (US), electroretinography (ERG), and optical coherence tomography were performed, confirming changes typical for *cmr*. Subsequently, the AS pedigree members were genetically and clinically tested, demonstrating autosomal recessive inheritance with no clinical symptoms in carrier animals, as was previously described for *cmr*. To our knowledge, this is the first reported case of canine multifocal retinopathy in the AS breed. Further investigations are under way.

Keywords

Australian Shepherd, BEST1, canine multifocal retinopathy, *cmr1*, multifocal retinal detachments, optical coherence tomography

Disciplines

Animal Diseases | Congenital, Hereditary, and Neonatal Diseases and Abnormalities | Eye Diseases | Medical Genetics | Medical Immunology | Ophthalmology | Veterinary Medicine

Canine multifocal retinopathy in the Australian Shepherd: a case report

Ingo Hoffmann^{*}, Karina E. Guziewicz[†], Barbara Zangerl[†], Gustavo D. Aguirre[†], and Christian Y. Mardin[‡]

^{*}Tieraerztliche Praxis für Augenheilkunde, 90471 Nuernberg, Germany

[†]Section of Ophthalmology, Department of Clinical Studies, University of Pennsylvania, Philadelphia, PA, USA

[‡]Universitätsaugenklinik der Friedrich-Alexander Universität Erlangen-Nuernberg, Erlangen, Germany

Abstract

A 1-year-old Australian Shepherd (AS) was presented for a routine hereditary eye examination. During the examination multiple raised, brown to orange lesions were noted in the fundus, which could not be attributed to a known retinal disease in this breed. As they clinically most closely resembled canine multifocal retinopathy (*cmr*) and no indication of an acquired condition was found, genetic tests for *BEST1* gene mutations were performed. These showed the dog to be homozygous for the *cmr1* (C73T/R25X) gene defect. Furthermore, ultrasound (US), electroretinography (ERG), and optical coherence tomography were performed, confirming changes typical for *cmr*. Subsequently, the AS pedigree members were genetically and clinically tested, demonstrating autosomal recessive inheritance with no clinical symptoms in carrier animals, as was previously described for *cmr*. To our knowledge, this is the first reported case of canine multifocal retinopathy in the AS breed. Further investigations are under way.

Keywords

Australian Shepherd; *BEST1*; canine multifocal retinopathy; *cmr1*; multifocal retinal detachments; optical coherence tomography

INTRODUCTION

Bestrophinopathies are a group of retinal diseases in which *BEST1*, a gene necessary for retinal pigment epithelium (RPE) function, is mutated.¹ In humans, this can lead to an early-onset vitelliform macular dystrophy called Best disease,² adult-onset foveomacular vitelliform dystrophy (AOFVD),³ autosomal dominant vitreoretinopathopathy (ADVIRC),⁴ and autosomal recessive bestrophinopathy (ARB).⁵

It has been shown that a clinically and genetically comparable disease exists in dogs, termed canine multifocal retinopathy (*cmr*).^{6,7} To date, three genetically different mutations were identified in dogs exhibiting the *cmr* phenotype. The most widespread of these, *cmr1* (C73T/R25X), was found to segregate thus far in seven individual Mastiff-derived breeds: Great Pyrenees, English Mastiff, Bullmastiff,⁶ Dogue de Bordeaux, Italian Mastiff,⁷ Bulldog, and

Perro de Presa Canario (Guziewicz KE and Zangerl B, unpublished). Contrary, the *cmr2*, a missense mutation (G482A/Gly161Asp), and *cmr3*, a frameshift mutation (C1388del/Pro463FS), are 'private' and, respectively, segregate in Coton de Tulear and Lapponian Herders only.^{6,7}

Despite the molecular differences, the disease manifests clinically as multifocal retinal bullae early in life, which progress until six to twelve months of age.⁸ It seems to be self-limited in most cases, although vision loss has also been described.⁷ So far, a specific treatment is not known, neither for *cmr* nor for human bestrophinopathies.^{9,10}

This case report details the clinical, ultrasonographic, electroretinographic, optical coherence tomographical (OCT), and genetic findings in an Australian Shepherd (AS). Clinical and molecular findings led to the diagnosis of *cmr1* in this breed.

CASE REPORT

Multiple fundic lesions were detected during a routine ophthalmic examination of a 1-year-old intact female AS following the guidelines of the European College of Veterinary Ophthalmology hereditary eye disease scheme. The owner had not noted any visual deficits. The dog was living as a companion dog in a rural area and had only been to Germany and Austria. It was fed commercial dog food and was routinely vaccinated against canine distemper, hepatitis, parainfluenza, parvovirus, leptospirosis, and rabies. It received deworming medications on a regular basis, the last time 3 months prior to the examination. On physical examination, the animal was healthy and alert, and abnormalities were limited to the eyes.

Upon ophthalmic examination, the adnexa, anterior segment, lens, and vitreous were normal. Fundoscopic examination showed multiple, brown to orange lesions, which were mainly limited to the tapetal fundus (Fig. 1). They mostly were 1 disc diameter in size, but could extend up to 4× the size of the optic disc and seemed vessel-associated. The bullae extended into the vitreous and had a bright border.

Despite the size and the number of the lesions, maze testing in the dark and ambient light as well as vision tests were considered normal and the dog was able to navigate in new areas with ease. Complete blood count and serum chemistry profile were within normal limits. Testing for toxoplasmosis showed no antibody titer. No progression of the lesions was noted 2 weeks after the initial examination. The presumptive diagnosis of *cmr* was made, but differential diagnoses included acquired inflammatory lesions, generalized neoplasia with metastases into the eyes, nutritional retinopathies, and congenital or genetic changes in the retina.

No signs of uveitis or choroiditis were present at either examination ruling out causes of exudative retinal detachments. Tapetal hyper-reflectivity as a sign of a reattached or degenerated retina as well as black pigmented centers with a hyper-reflective rim like in post-inflammatory lesions were also not observed. Furthermore, the clinical laboratory results showed no abnormalities. A systemic neoplastic affection seemed unlikely due to nonprogression of the lesion, the good body condition, and age of the dog. The multifocal presence of the retinal detachments could have led to the diagnosis of multifocal retinal dysplasia, but this disease normally has an opaque and vermiform or donut-like appearance.

As the disease resembled clinically *cmr*, EDTA blood was collected according to standard veterinary care and tested for known canine *BEST1* mutations (OptiGen, LLC). Genetic results identified the dog to be homozygous for the *cmr1* gene defect.

Subsequently, the owner consented to further examinations to better characterize the fundus changes. Therefore, ultrasonography (US), electroretinography (ERG), and OCT were performed under sedation because of the dog's anxiety. For the latter, an intravenous dose of 0.04 mg/kg of Medetomidin was used. The cornea was topically anesthetized with 0.5% proparacaine (Proparacain-POS; Ursapharm, Saarbruecken, Germany). Ultrasound (Cineloop Scan-S; Quantel Medical, Clermont-Ferrand, France) was performed with an ophthalmic 10 MHz transducer scanning the intraocular and orbital contents. It showed multiple semi-curved hyperechoic lines that protruded into the vitreous and were consistent with focal, serous retinal detachments (Fig. 2).

Scotopic and photopic electroretinograms (RETIport; S&V Technologies AG, Hennigsdorf, Germany) of the dog as well as a breed-, age-, and gender-matched control were recorded. Mydriasis was accomplished with topical application of tropicamide 5% (Mydrum, Ankerpharm, Germany), and the dogs were dark-adapted for 10 min. Two subdermal needle electrodes (GVB-geliMED E.Kfm, Bad Segeberg, Germany) were placed as previously described.¹¹ A Kojiman corneal contact lens was used as an active electrode and as an eyelid speculum. Its in-built 4WLED was used as photostimulator (3.0 cds/m² standard flash, 300 Hz) and it was stabilized on the cornea with a dexpanthenol gel (Corneregel, Bausch & Lomb, Berlin, Germany). Each ERG response was averaged 20 times, and the cut-off filter was set at 300 Hz. Scotopic and photopic electroretinography revealed a significant difference in the b-waves in the affected dog and the control (Fig. 3). Optical coherence tomography (OCT) was completed only in the affected dog (SPECTRALIS® Tracking Laser Tomographie with Eye Tracking; Heidelberg Engineering, Heidelberg, Germany). The vitreous and retina as well as the bullous retinal lesions were photographed. The lesions were measured, again confirming the serous retinal detachments. Focal serous accumulations, which were optically opaque in some cases, were observed subretinally. In places, where both occurred, a gravity stratification was visible, that is, the serous material was located above the opaque one. In this area, the retina was thickened compared to the thickness of the retina that was attached on either side of the bulla (Fig. 4). The thickness of the affected and unchanged areas was 88–216 and 59–67 µm, respectively, measured from internal limiting membrane to external limiting membrane.

As clinical and genetic results were highly consistent with a diagnosis of *cmr1*, five directly related animals were clinically examined and tested for the *cmr1* mutation. While none of the relatives showed clinical abnormalities, the parents of the affected dog were identified to be *cmr1* carriers, and other relatives were genetically normal (Fig. 5). Additionally, the investigation into genetic markers surrounding the original mutation suggested that it is identical-by-descent (IBD) with the locus originally described in Mastiff-related breeds (data not shown).

DISCUSSION

To date, clinical implications of *cmr* are not clearly understood. Ocular symptoms range from normal to severe visual impairment. The affected AS was presented for a routine eye examination without the indication of reduced vision despite the presence of large and prominent retinal lesions. As there were no signs of an infectious origin for the retinal changes or other known potential causes, striking resemblance to already described cases of *cmr* suggested this disorder as potential diagnosis.^{8,11} Ophthalmic ultrasound showed multiple zones of dehiscence of the sensory retina from the RPE which can be indicative, but not specific for *cmr*.¹¹

Electrodiagnostic testing was distinctively different in the affected animal from a breed-, age-, and gender-matched control. Although not common with *cmr*, sporadic cases with

altered ERG responses have previously been observed.¹¹ The reason for this is unknown. It may be possible that the severity or location of the lesions contributed to the diminishing of the b-wave, although the dog seemed not to be visually impaired by this. It may be worthwhile to conduct ERG's in affected ASs with less prominent changes to see whether the severity of the lesions correlates with b-wave amplitude. The OCT examination further strengthened the diagnosis of *cmr* as it confirmed the serous retinal detachments and the subretinal infiltrate. This infiltrate has been identified in other cases of this disease¹¹ as well as in humans affected with Best's disease.¹² The thickness of the affected areas was unusual for *cmr*¹¹ and is not typically seen in Best's disease either.¹³ In contrast to a previous report,¹¹ the retina did not seem thinned compared to the thickness of the retina that was attached on either side of the bulla (Fig. 4). This may be due to the young age of the animal and the unknown onset of individual lesions. Thus, thinning of the retina may potentially occur at a later stage.

Genotype analyses of the affected dog and its immediate family not only confirmed the diagnosis of *cmr1*, but also revealed an identity-by-descent at the *BEST1* locus between AS and Mastiff breeds. This suggests that ASs either share some common ancestry with Mastiff-related breeds or at least some lines may have been subjected to a recent admixture. As the latter is not supported by the documented breeding history, these findings not only have an immediate impact on the AS breed, but also suggest that *cmr1* may indeed reflect an old mutation with the potential to affect more breeds than initially thought.

In conclusion, a genetic test for *cmr1* is warranted for ASs suspicious for the disease. Furthermore, *cmr* should be added to the list of differential diagnoses in retinal changes in this breed.

Acknowledgments

The authors thank Sue Pearce-Kelling from OptiGen LLC (Ithaca, NY) for samples management and support with genetic testing as well as Barbara Nell and Petra Benz from the University of Veterinary Medicine (Vienna, Austria) for examining and sample acquisition of the dog's relatives in Austria.

References

1. Lorenz B, Preising MN. Morbus Best. *Der Ophthalmologe*. 2005; 102:111–115. [PubMed: 15657691]
2. Petrukhin K, Koisti MJ, Bakall B, et al. Identification of the gene responsible for Best macular dystrophy. *Nature Genetics*. 1998; 19:241–247. [PubMed: 9662395]
3. Seddon JM, Afshari MA, Sharma S, et al. Assessment of mutations in the Best macular dystrophy (VMD2) gene in patients with adult-onset foveomacular vitelliform dystrophy, age-related maculopathy, and bull's-eye maculopathy. *Ophthalmology*. 2001; 108:2060–2067. [PubMed: 11713080]
4. Yardley J, Leroy BP, Hart-Holden N, et al. Mutations of VMD2 splicing regulators cause nanophthalmos and autosomal dominant vitreoretinopathopathy (ADVIRC). *Investigative Ophthalmology & Visual Science*. 2004; 45:3683–3689. [PubMed: 15452077]
5. Burgess R, Millar ID, Leroy BP, et al. Biallelic mutation of BEST1 causes a distinct retinopathy in humans. *American Journal of Human Genetics*. 2008; 82:19–31. [PubMed: 18179881]
6. Guziewicz KE, Zangerl B, Lindauer SJ, et al. Bestrophin gene mutations cause canine multifocal retinopathy, a novel animal model for Best disease. *Investigative Ophthalmology and Visual Science*. 2007; 48:1959–1967. [PubMed: 17460247]
7. Zangerl B, Wickström K, Slavik J, et al. Assessment of canine BEST1 variations identifies new mutations and establishes an independent bestrophinopathy model (*cmr3*). *Molecular Vision*. 2010; 16:2791–2804. [PubMed: 21197113]

8. Grahn BH, Philibert H, Cullen CL, et al. Multifocal retinopathy of Great Pyrenees dogs. *Veterinary Ophthalmology*. 1998; 1:211–221. [PubMed: 11397233]
9. Guzewicz, KE.; Komaromy, AM.; Hauswirth, WW., et al. Evaluation of AAV-mediated BEST1 expression in the canine retina. *Association for Research in Vision and Ophthalmology (ARVO) Annual Meeting*; 2011, May 1–5; Fort Lauderdale, FL.
10. Boon CJ, Klevering BJ, Leroy BP, et al. The spectrum of ocular phenotypes caused by mutations in the BEST1 gene. *Progress in Retinal and Eye Research*. 2009; 28:187–205. [PubMed: 19375515]
11. Grahn BH, Sandmeyer LS, Breaux CB. Retinopathy of Coton de Tulear dogs: clinical manifestations, electroretinographic, ultrasonographic, fluorescein and indocyanine green angiographic, and optical coherence tomographic findings. *Veterinary Ophthalmology*. 2008; 11:242–249. [PubMed: 18638350]
12. Pianta MJ, Aleman TS, Cideciyan AV, et al. In vivo micropathology of Best macular dystrophy with optical coherence tomography. *Experimental Eye Research*. 2003; 76:203–211. [PubMed: 12565808]
13. Querques G, Regenbogen M, Soubrane G, et al. High-resolution spectral domain OCT findings in multifocal vitelliform macular dystrophy. *Survey of Ophthalmology*. 2009; 54:311–316.

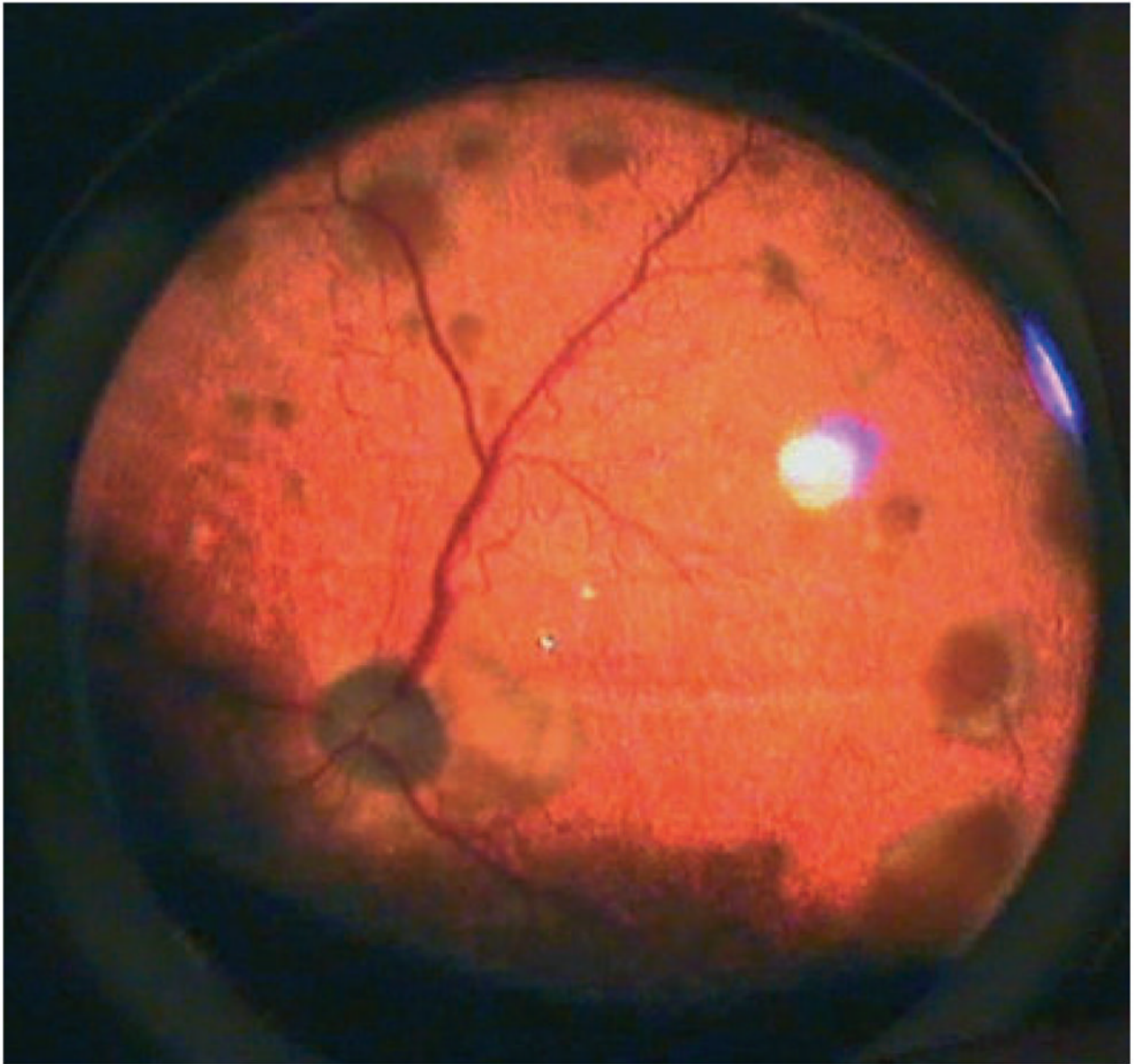


Figure 1.
Right fundus photograph of the affected Australian Shepherd with multiple, brown to orange lesions.

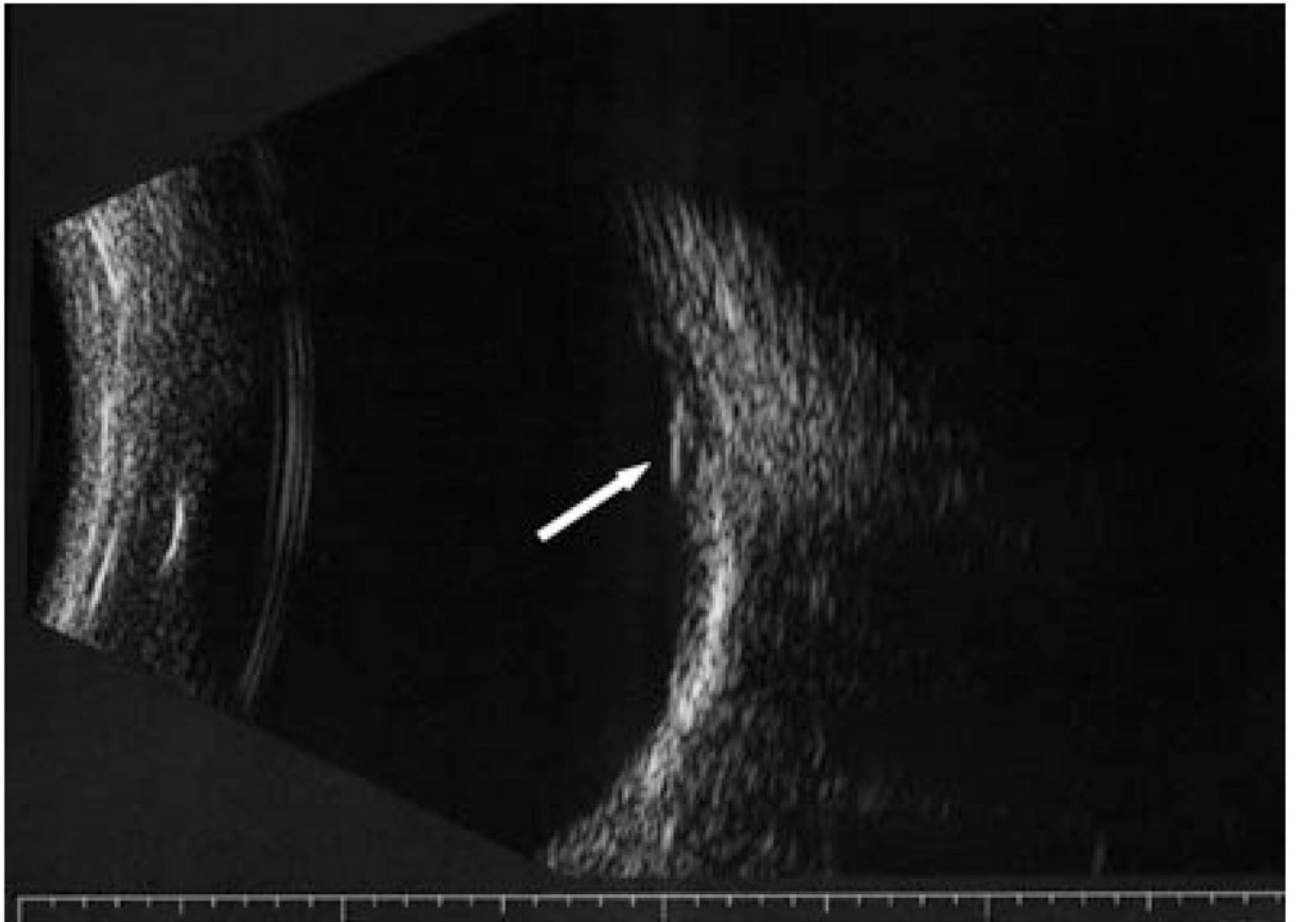


Figure 2. Ultrasonogram of the right eye with a serous detachment. Note the hyperechoic line that protrudes into the vitreous (arrow).

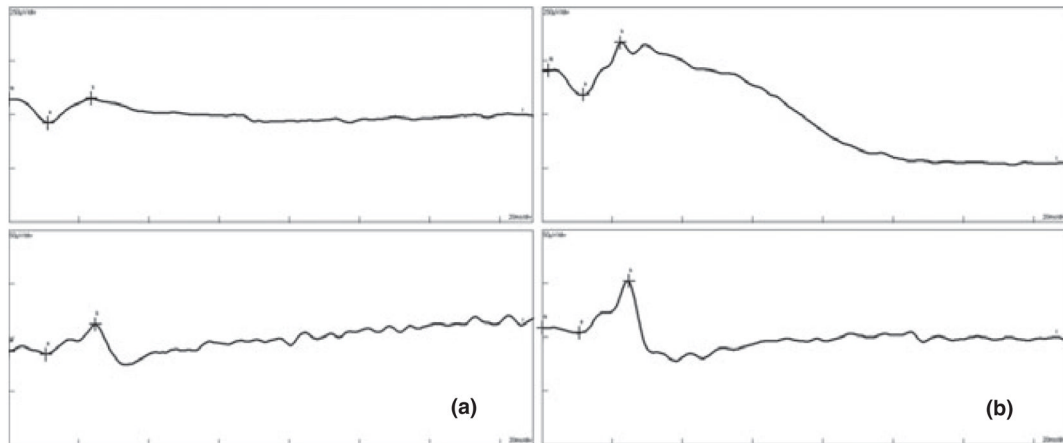


Figure 3. Electrophysiology measurements of the studied Australian Shepherd case (a) and the control dog (b). Scotopic measurement on top, and photopic measurement below. Note the diminished b-wave in (a).

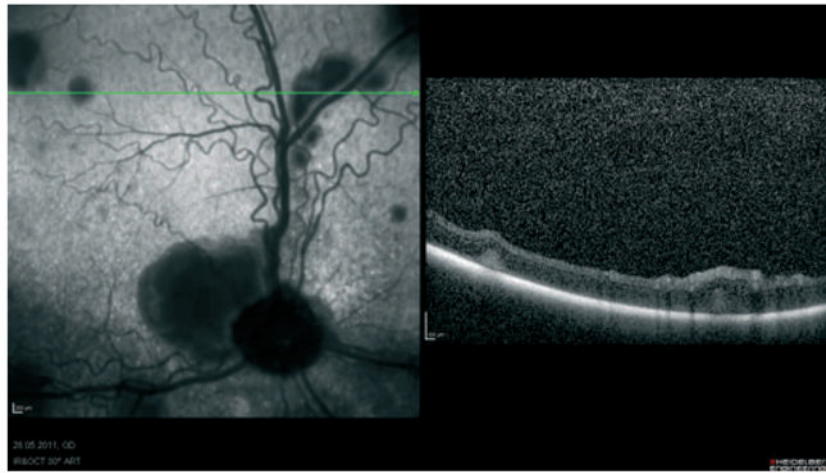


Figure 4. Optical coherence tomography in affected Australian Shepherd. The green line in the left photograph shows the scanned area depicted on the right side of the figure. Note the focal detachments, the serous accumulations with gravity stratification, and the thickened retina over the larger bulla.

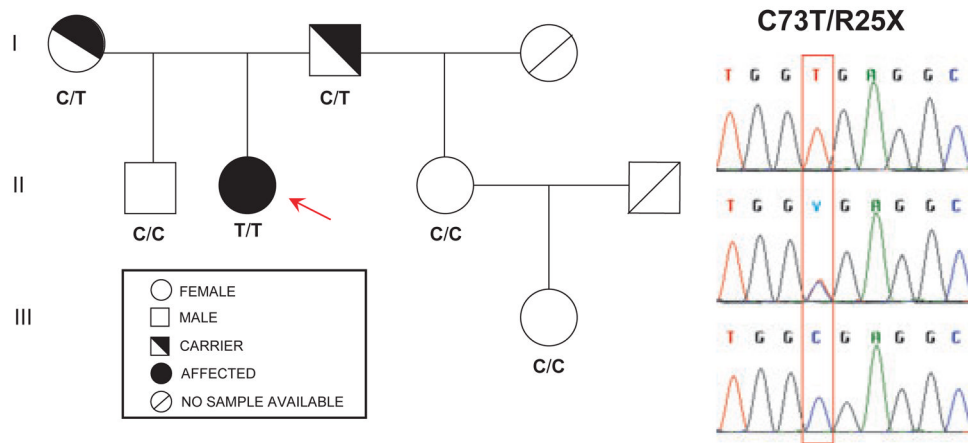


Figure 5. (a) Australian Shepherd pedigree segregating *cmr1* mutation (C, normal allele; T, mutant allele). The affected case is denoted by the red arrow. (b) Sequencing chromatograms illustrating the C73T/R25X mutation in the canine *BEST1* gene (top panel: homozygous affected; middle panel: heterozygous carrier; bottom panel: homozygous for the normal allele).