



4-2013


Topical and Systemic Therapies for Oral and Perioral Herpes Simplex Virus Infections

Eric T. Stoopler

University of Pennsylvania, ets@dental.upenn.edu

Ramesh Balasubramanlam

Follow this and additional works at: https://repository.upenn.edu/dental_papers

 Part of the [Oral Biology and Oral Pathology Commons](#), [Pathological Conditions, Signs and Symptoms Commons](#), [Skin and Connective Tissue Diseases Commons](#), and the [Virus Diseases Commons](#)

Recommended Citation

Stoopler, E. T., & Balasubramanlam, R. (2013). Topical and Systemic Therapies for Oral and Perioral Herpes Simplex Virus Infections. *California Dental Association Journal*, 41 (4), 259-262. Retrieved from https://repository.upenn.edu/dental_papers/39

Read the full issue at http://www.cda.org/Portals/0/journal/journal_042013.pdf

This paper is posted at ScholarlyCommons. https://repository.upenn.edu/dental_papers/39
For more information, please contact repository@pobox.upenn.edu.

Topical and Systemic Therapies for Oral and Perioral Herpes Simplex Virus Infections

Abstract


Oral and perioral herpes simplex virus (HSV) infections in healthy individuals often present with signs and symptoms that are clearly recognized by oral health care providers (OHCPs). Management of these infections is dependent upon a variety of factors and several agents may be used for treatment to accelerate healing and decrease symptoms associated with lesions. This article will review the pertinent aspects of topical and systemic therapies of HSV infections for the OHCP.

Disciplines

Dentistry | Oral Biology and Oral Pathology | Pathological Conditions, Signs and Symptoms | Skin and Connective Tissue Diseases | Virus Diseases

Comments

Read the full issue at http://www.cda.org/Portals/0/journal/journal_042013.pdf



Topical and Systemic Therapies for Oral and Perioral Herpes Simplex Virus Infections

ERIC T. STOOPLER, DMD, FDS RCSED, AND RAMESH BALASUBRAMANIAM, BDSC, MS

ABSTRACT Oral and perioral herpes simplex virus (HSV) infections in healthy individuals often present with signs and symptoms that are clearly recognized by oral health care providers (OHCPs). Management of these infections is dependent upon a variety of factors and several agents may be used for treatment to accelerate healing and decrease symptoms associated with lesions. This article will review the pertinent aspects of topical and systemic therapies of HSV infections for the OHCP.

AUTHORS

Eric Stoopler, DMD, FDS RCSED, is an associate professor of Oral Medicine and director of the Postdoctoral Oral Medicine program at the University of Pennsylvania School of Dental Medicine. *Conflict of Interest Disclosure: None reported.*

Ramesh Balasubramaniam, BDSC, MS, is a clinical associate professor at the School of Dentistry, University of Western Australia in Perth, Australia. *Conflict of Interest Disclosure: None reported.*

Oral and perioral (herein referred to collectively as oral) herpes simplex virus (HSV) infections represent one of the most common oral soft tissue disease processes encountered in the general population.^{1,2} HSV-1 serotype is the most common cause of orofacial infections, however, HSV-2 serotype has been implicated as a causative agent of these infections (and HSV-1 as the etiology for genital infections) due to sexual practices.^{3,4} Primary oral HSV infections usually occur in early childhood and while the majority are subclinical, clinical infections initially present with general symptoms, such as malaise, fever and lymphadenopathy (referred to as a prodrome) followed by vesicles and/or ulcers affecting a variety of intraoral

surfaces.³ Most primary oral HSV infections are readily diagnosed based on clinical history, signs and symptoms and further laboratory investigation is generally not warranted.^{2,5} The majority of oral HSV infections are self-limiting with resolution usually within two weeks, often requiring only palliative treatment and supportive care as needed.³

Following primary infection, the virus migrates to the trigeminal nerve ganglion where it can remain latent indefinitely but may be stimulated to reactivate under a variety of circumstances (environmental triggers, stress, illness, etc.) that results in clinical infection.³ The most common presentation of recrudescing HSV infection (development of clinical lesions) in healthy individuals is recurrent herpes labialis (RHL), observed as a lesion located

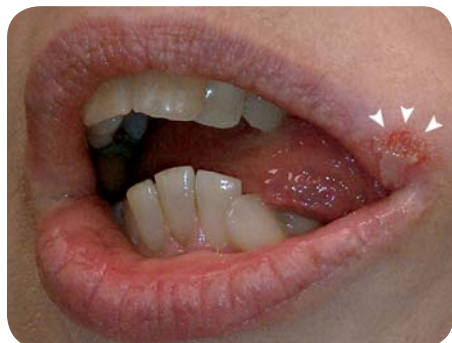

FIGURE 1. Typical presentation of recurrent herpes labialis (RHL) (white arrows). (Courtesy of Martin Greenberg, DDS, and Thamer Musbah, BDS, University of Pennsylvania.)

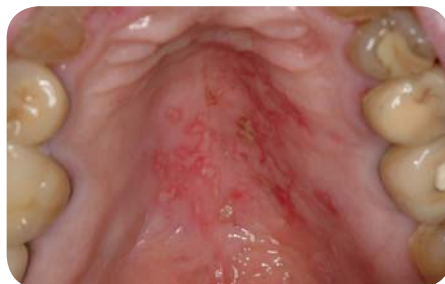

FIGURE 2. Recurrent intraoral herpes (RIH) of the palatal mucosa. (Courtesy of Martin Greenberg, DDS, University of Pennsylvania.)

at the mucocutaneous junction of the lips (known as a fever blister or cold sore) (FIGURE 1). A majority of patients experience prodromal symptoms preceding an episode of RHL, which often consists of pain, itching and/or burning at the site of lesion development.⁶ Recurrent intraoral herpes (RIH), which is observed more often in immunocompromised patients, may be difficult to distinguish clinically from other oral mucosal disorders, such as aphthous stomatitis (FIGURE 2). Prodromal symptoms preceding an episode of RIH are not commonly observed.⁶ Management of recurrent herpes infections is dependent upon frequency, severity and distribution of lesions and may include topical and/or systemic therapeutic agents.

Topical Therapies

Topical therapies for oral HSV infections can be divided into palliative, preventive and antiviral categories. Palliative topical agents available over the counter (OTC) commonly contain the anesthetic benzocaine and are beneficial in reducing pain associated with an oral HSV infection. Palliative topical agents available by prescription, such as lidocaine gel 2 percent, viscous lidocaine 2 percent or mixtures of topical anesthetic with coating agents +/- diphenhydramine (e.g., magic mouthwash) may afford patients more relief compared to OTC topical anesthetic preparations. These agents may be used for both primary and recurrent oral HSV

infections in adults for symptomatic relief and are often used in combination with systemic antiviral agents for more effective management. Other topical agents that have been recommended for use to treat RHL include ice and lip compounds containing lanolin, cocoa butter or petrolatum-based products.⁶

Use of topical anesthetic preparations in the pediatric population is controversial due to possible increased risk of life-threatening events.^{7,8} Aspiration of topical lidocaine in this population has been linked to adverse neurologic and cardiovascular reactions, such as seizures and hypotensive episodes, respectively^{9,10} while ingestion of topical benzocaine has been associated with development of methemoglobinemia.^{8,11} In April 2011, the Food and Drug Administration (FDA) issued a safety alert regarding topical benzocaine products (sprays, liquids, gels) in association with risk of methemoglobinemia and recommended that benzocaine products not be used on children younger than 2 years of age, except under the advice and supervision of a health care professional.¹²

Preventive agents are primarily used for decreasing the risk of an RHL episode, especially if a patient is aware of precipitating factors, such as sun exposure. Evidence supports using sunscreen on the lips with a sun-protection factor (SPF) of at least 15 to decrease the risk of developing an episode of RHL.^{4,13}

Topical antiviral agents have demonstrated efficacy in accelerating the healing time of RHL lesions, especially if administered during the prodromal phase.⁶ The topical antiviral agents that are most commonly recommended to treat RHL include Acyclovir 5 percent cream, Penciclovir 1 percent cream and Docosanol 10 percent cream.^{1,2,4,13} Acyclovir is a nucleoside analogue of guanosine with a selective affinity for thymidine kinase (TK), which is necessary for activation of acyclovir, in virus-infected cells.¹ Acyclovir is a potent inhibitor of viral DNA synthesis and thus ultimately prevents viral replication.¹ Penciclovir is an acyclic guanine derivative with a similar antiviral spectrum as acyclovir. It is also phosphorylated by viral TK and inhibits viral DNA polymerase.^{1,14} Penciclovir has approximately 1/100th the potency of acyclovir, but is an effective antiviral agent due to its long half-life and high intracellular concentrations.¹ Docosanol is a 22-carbon primary alcohol that blocks the virus from attaching to cells via interference of epithelial cell surface receptors and viral envelope proteins.⁶ Acyclovir 5 percent cream and Penciclovir 1 percent cream are available by prescription, while Docosanol is the only agent approved by the FDA as an OTC product for treatment of RHL.

Topical formulations of foscarnet, cidofovir and imiquimod are generally reserved for treatment of RHL lesions that are nonresponsive to typical antiviral agents and are rarely used in healthy individuals.^{1,4,15} In contrast to other antiviral agents dependent upon viral TK, foscarnet and cidofovir inhibit viral DNA synthesis independently of this mechanism.¹ Foscarnet has demonstrated efficacy in treating acyclovir-resistant HSV infections, while cidofovir is generally reserved for both acyclovir and foscarnet-resistant HSV infections.¹⁴ Imiquimod

TABLE 1

Topical Therapies for Treatment of Oral HSV Infections

Category	Agent	Indications	Recommendations
Palliative	Ice, lip balms Over-the-counter topical anesthetic preparations (e.g., containing benzocaine)‡	Primary HSV infections, Recurrent HSL infections, RIH infections	As needed or per manufacturer's instructions.
	Topical lidocaine preparations* (Viscous lidocaine 2%, lidocaine gel 2%)	Primary HSV infections, Recurrent HSL infections, RIH infections	Viscous lidocaine 2% - 10 ml swish and spit as needed for pain relief. Lidocaine gel 2% - apply layer to affected area as needed for pain relief.
	Magic Mouthwash**	Primary infections, RIH infections	10 ml swish and spit as needed for pain relief.
Protective	Sunscreen (SPF 15 or higher)	Recurrent HSL infections	As per manufacturer's instructions.
Antiviral	Acyclovir 5% cream	Recurrent HSL infections	Apply every two hours from the time of prodrome until lesions are healed.
	Penciclovir 1% cream	Recurrent HSL infections	Apply every two hours from the time of prodrome until lesions are healed.
	Docosanol 10% cream	Recurrent HSL infections	Apply every two hours from the time of prodrome until lesions are healed.
	Topical foscarnet, cidofovir and/or imiquimod	Recalcitrant HSV lesions	Rarely used in healthy individuals; Refer to appropriate health care provider for management with these agents.

‡ Food and Drug Administration recommends benzocaine products (spray, liquid, gel) should not be used on children younger than 2 years of age, except under the advice and supervision of a health care professional.

* Aspiration of topical lidocaine in the pediatric population has been associated with adverse neurologic and/or cardiovascular side effects.

‡ Various combinations of agents — usually contains topical anesthetic (e.g., viscous lidocaine 2%) with coating agents (e.g., Maalox) + / - diphenhydramine.

is a novel agent that enhances innate immunologic responses to viruses and topical formulations has shown to be effective in treating resistant HSV infection in the setting of HIV.¹⁵ **TABLE 1** outlines the indications and usage recommendations for topical agents used for treatment of oral HSV infections.

Systemic Therapies

Systemic therapies may be required for the treatment of primary oral HSV infection and treatment or prophylaxis of both RHL and RIH, especially in immunocompromised patients. Unlike topical agents, systemic medications enable greater drug exposure, rapid access to site of viral replication, better biocompatibility, less frequent dosing and improved compliance. Systemic medications are exclusively antiviral agents and may be administered orally or intravenously.^{16,17}

As noted previously, treatment of

primary oral HSV infection is typically based on supportive and symptomatic interventions.¹⁸ However, off-label use of systemic antiviral medications may accelerate healing time of primary oral HSV lesions by inhibiting DNA replication of infected cells if commenced when prodromal symptoms are recognized or within one day of vesicle eruption.⁶ Oral acyclovir 200 mg five times a day or 400 mg three times a day for 10 days may be used in severe cases of primary oral HSV infection in adults as currently prescribed in primary genital infection.⁶ In the pediatric patient, treatment with oral acyclovir suspension 15 mg/kg within three days of symptom onset and continued five times a day for one week was shown to accelerate healing, reduce viral shedding and improve oral intake.¹⁹

Contemporary antiviral medications such as famciclovir and valacyclovir may also be prescribed given their more convenient dosing and increased

bioavailability.¹⁴ (**TABLE 2**) Famciclovir (prodrug of penciclovir) is a diacetyl-6-deoxy analogue that is rapidly absorbed and undergoes deacetylation in the gastrointestinal tract, blood and liver to its active form.¹ Valacyclovir (prodrug of acyclovir) is an L-valine ester that is well absorbed and 99 percent converted to its active form in the gastrointestinal tract and liver.¹ This results in a three- to five-times increase in bioavailability.¹⁴

Systemic antiviral medications may be used as prophylaxis or treatment in patients with severe, frequent, persistent and unsightly outbreaks.²⁰ Oral valacyclovir has been shown to be effective and is approved by the FDA for the treatment of RHL.¹⁷ Oral acyclovir and famciclovir are approved by the FDA specifically for the treatment and suppression of genital herpes, but have also been used for RHL therapy.^{13,21}

In the immunocompromised individual, such as during chemotherapy or during

TABLE 2

Systemic Antiviral Medications for the Treatment of Primary Herpes Simplex Virus Infection

	Acyclovir	Valacyclovir	Famciclovir
Dose	200 mg *	400 mg +	1000 mg *
Frequency	5x/day	3x/day	2x/day
Duration	7-10 days	7-10 days	7-10 days

* Food and Drug Administration treatment recommendations for genital herpes

+ Recommendations from the Center for Disease Control and Prevention for genital herpes

TABLE 3

Systemic Therapies for Treatment of Oral HSV Infections

Indication	Therapy
Treatment of RHL in the immunocompetent host	Oral acyclovir 400 mg three times a day for five to seven days Oral valacyclovir 500 mg to 2000 mg twice a day for one day Oral famciclovir 500 mg two to three times a day for three days
Prophylaxis of RHL in the immunocompetent host *	Oral acyclovir 400 mg two to three times a day Oral valacyclovir 500 mg to 2000 mg twice a day
Treatment of recurrent HSV infections in the immunocompromised host	Oral acyclovir 400 mg three times a day for 10 days or longer as necessary Oral valacyclovir 500-1000 mg twice a day for 10 days or longer as necessary Oral famciclovir 500 mg twice a day for up to one year
Prophylaxis of recurrent HSV infections in the immunocompromised host	Oral acyclovir 400-800 mg three times a day Oral valacyclovir 500-1000 mg twice a day Oral famciclovir 500-1000 mg twice a day

Adapted and modified from Woo SB, Challacombe SJ. "Management of recurrent oral herpes simplex infections." *Oral Surg Oral Med Oral Pathol Oral Radiol Endod* 2007;103 (suppl 1): S12.e1-S12.e18.

* Duration of the prophylaxis is based on the extent and frequency of exposure to triggers of RHL episodes, such as sunlight, dental treatment, etc.

the use of immunosuppressive drugs, RIH may present as a severe outbreak.²² Oral or intravenous acyclovir has been shown to be effective in the prevention and treatment of RIH in these patients.²³ Similarly, valacyclovir and famciclovir may also be prescribed for the prevention and treatment of RIH in immunocompromised patients. **TABLE 3** summarizes the antiviral agents available, their dosages and duration of use based on the expert recommendations from the Fourth World Workshop in Oral Medicine.¹³ Newer intravenous medications such as foscarnet and cidofovir may be necessary in acyclovir-resistant, severely immunocompromised patients. These medications are highly nephrotoxic and should be used with caution.²¹

Conclusions

There is a variety of treatment modalities for oral HSV infections. OHCPs must be cognizant of the advantages and limitations of both topical and systemic therapies for this condition. It is imperative for OHCPs to determine the appropriate agents for treatment in the context of the patient's disease presentation and overall medical status. ■■■■

REFERENCES

1. Arduino PG, Porter SR. Oral and perioral herpes simplex virus type 1 (HSV-1) infection: review of its management. *Oral Dis* 2006;12:254-270.
2. Cunningham A, Griffiths P, Leone P, Mindel A, Patel R, Stanberry L, Whitley R. Current management and recommendations for access to antiviral therapy of herpes labialis. *J Clin Virol* 2012;53:6-11.

3. Stoopler ET. Oral herpetic infections (HSV 1-8). *Dent Clin North Am* 2005;49:15-29, vii.
4. Fatahzadeh M, Schwartz RA. Human herpes simplex labialis. *Clin Exp Dermatol* 2007;32:625-630.
5. Stoopler ET, Pinto A, DeRossi SS, Sollecito TP. Herpes simplex and varicella-zoster infections: clinical and laboratory diagnosis. *Gen Dent* 2003;51:281-6; quiz 287.
6. Fatahzadeh M, Schwartz RA. Human herpes simplex virus infections: epidemiology, pathogenesis, symptomatology, diagnosis, and management. *J Am Acad Dermatol* 2007;57:737-63; quiz 764-6.
7. Faden H. Management of primary herpetic gingivostomatitis in young children. *Pediatr Emerg Care* 2006;22:268-269.
8. So TY, Farrington E. Topical benzocaine-induced methemoglobinemia in the pediatric population. *J Pediatr Health Care* 2008;22:335-9; quiz 340-1.
9. Hess GP, Walson PD. Seizures secondary to oral viscous lidocaine. *Ann Emerg Med* 1988;17:725-727.
10. Garrettson LK, McGee EB. Rapid onset of seizures following aspiration of viscous lidocaine. *J Toxicol Clin Toxicol* 1992;30:413-422.
11. Chung NY, Batra R, Itzkevitch M, Borucho D, Baldauf M. Severe methemoglobinemia linked to gel-type topical benzocaine use: a case report. *J Emerg Med* 2010;38:601-606.
12. [Anonymous]. Benzocaine topical products: sprays, gels and liquids - risk of methemoglobinemia. U.S. Food and Drug Administration; U.S. Department of Health and Human Services. 04/07/2011; Accessed August 16, 2012.
13. Woo SB, Challacombe SJ. Management of recurrent oral herpes simplex infections. *Oral Surg Oral Med Oral Pathol Oral Radiol Endod* 2007;103 (suppl 1): S12.e1-S12.e18.
14. Balfour HH Jr. Antiviral drugs. *N Engl J Med* 1999;340:1255-68.
15. Hirokawa D, Woldow A, Lee SN, Samie F. Treatment of recalcitrant herpes simplex virus with topical imiquimod. *Cutis* 2011;88:276-277.
16. Laiskonen A, Thune T, Neldam S, Hiltunen-Back E. Valacyclovir in the treatment of facial herpes simplex virus infection. *J Infect Dis* 2002;186 Suppl 1:S66-70.
17. Spruance SL, Jones TM, Blatter MM, Vargas-Cortes M, Barber J, Hill J, Goldstein D, Schultz M. High-dose, short-duration, early valacyclovir therapy for episodic treatment of cold sores: results of two randomized, placebo-controlled, multicenter studies. *Antimicrob Agents Chemother* 2003;47:1072-80.
18. Lynch DP. Oral viral infections. *Clin Dermatol* 2000;18:619-28.
19. Amir J, Harel L, Smetana Z, Varsano I. Treatment of herpes simplex gingivostomatitis with aciclovir in children: a randomised double blind placebo controlled study. *BMJ* 1997;314:1800-3.
20. Simmons A. Clinical manifestations and treatment considerations of herpes simplex virus infection. *J Infect Dis* 2002;186 Suppl 1:S71-7.
21. Chilukuri S, Rosen T. Management of acyclovir-resistant herpes simplex virus. *Dermatol Clin* 2003;21:311-20.
22. Greenberg MS. Herpesvirus infections. *Dent Clin North Am* 1996;40:359-68.
23. Greenberg MS, Friedman H, Cohen SG, Oh SH, Laster L, Starr S. A comparative study of herpes simplex infections in renal transplant and leukemic patients. *J Infect Dis* 1987;156:280-7.

THE CORRESPONDING AUTHOR, Eric T. Stoopler, DMD, FDS RCSEd, can be reached at ets@dental.upenn.edu.