University of Pennsylvania
ScholarlyCommons

Neuroethics Publications

Center for Neuroscience & Society

4-10-2001

The measurement of regional cerebral blood flow during the complex cognitive task of meditation: a preliminary SPECT study

Andrew B. Newberg
University of Pennsylvania, andrew.newberg@uphs.upenn.edu

Abass Alavi
University of Pennsylvania, ALAVI@OASIS.RAD.UPENN.EDU

Michael J. Baime
University of Pennsylvania, baime@mail.med.upenn.edu

Michael Pourdehnad
University of Pennsylvania

Jill Santanna
University of Pennsylvania

See next page for additional authors

Postprint version. Published in *Psychiatry Research: Neuroimaging*, Volume 106, Issue 2, April 2001, pages 113-122.
Publisher URL: http://dx.doi.org/10.1016/S0925-4927(01)00074-9

This paper is posted at ScholarlyCommons. http://repository.upenn.edu/neuroethics_pubs/25
For more information, please contact repository@pobox.upenn.edu.

The measurement of regional cerebral blood flow during the complex cognitive task of meditation: a preliminary SPECT study

Abstract
This study measured changes in regional cerebral blood flow (rCBF) during the complex cognitive task of meditation using single photon emission computed tomography. Eight experienced Tibetan Buddhist meditators were injected at baseline with 7 mCi HMPAO and scanned 20 min later for 45 min. The subjects then meditated for 1 h at which time they were injected with 25 mCi HMPAO and scanned 20 min later for 30 min. Values were obtained for regions of interest in major brain structures and normalized to whole brain activity. The percentage change between meditation and baseline was compared. Correlations between structures were also determined. Significantly increased rCBF ($P<0.05$) was observed in the cingulate gyrus, inferior and orbital frontal cortex, dorsolateral prefrontal cortex (DLPFC), and thalamus. The change in rCBF in the left DLPFC correlated negatively ($P<0.05$) with that in the left superior parietal lobe. Increased frontal rCBF may reflect focused concentration and thalamic increases overall increased cortical activity during meditation. The correlation between the DLPFC and the superior parietal lobe may reflect an altered sense of space experienced during meditation. These results suggest a complex rCBF pattern during the task of meditation.

Keywords
frontal cortex, thalamus, single photon emission computed tomography

Comments
Postprint version. Published in *Psychiatry Research: Neuroimaging*, Volume 106, Issue 2, April 2001, pages 113-122.
Publisher URL: http://dx.doi.org/10.1016/S0925-4927(01)00074-9

Author(s)
Andrew B. Newberg, Abass Alavi, Michael J. Baime, Michael Pourdehnad, Jill Santanna, and Eugene d'Aquili

This journal article is available at ScholarlyCommons: http://repository.upenn.edu/neuroethics_pubs/25

Newberg A, Alavi A, Baime M, Pourdehnad M, Santanna J, and d'Aquili E: The measurement of regional cerebral blood flow during the complex cognitive task of meditation: a preliminary SPECT study. Psychiatry Research 4/10/2001;106(2):113-22.

Andrew Newberg[a,*], Abass Alavi[a], Michael Baime[b], Michael Pourdehnad[a], Jill Santanna[c], Eugene d'Aquili[d]

[a] *Division of Nuclear Medicine, Department of Radiology, University of Pennsylvania Medical Center, Philadelphia, PA 19104, USA*
[b] *Department of Medicine, University of Pennsylvania Medical Center, Philadelphia, PA, USA*
[c] *Department of Biostatistics and Epidemiology, University of Pennsylvania Medical Center, Philadelphia, PA, USA*
[d] *(Deceased), Previously Department of Psychiatry, University of Pennsylvania Medical Center, Philadelphia, PA, USA*

Abstract

This study measured changes in regional cerebral blood flow (rCBF) during the complex cognitive task of meditation using single photon emission computed tomography. Eight experienced Tibetan Buddhist meditators were injected at baseline with 7 mCi HMPAO and scanned 20 min later for 45 min. The subjects then meditated for 1 h at which time they were injected with 25 mCi HMPAO and scanned 20 min later for 30 min. Values were obtained for regions of interest in major brain structures and normalized to whole brain activity. The percentage change between meditation and baseline was compared. Correlations between structures were also determined. Significantly increased rCBF ($P < 0.05$) was observed in the cingulate gyrus, inferior and orbital frontal cortex, dorsolateral prefrontal cortex (DLPFC), and thalamus. The change in rCBF in the left DLPFC correlated negatively ($P < 0.05$) with that in the left superior parietal lobe. Increased frontal rCBF may reflect focused concentration and thalamic increases overall increased cortical activity during meditation. The correlation between the DLPFC and the superior parietal lobe may reflect an altered sense of space experienced during meditation. These results suggest a complex rCBF pattern during the task of meditation. © 2001 Elsevier Science Ireland Ltd. All rights reserved.

Keywords: Frontal cortex; Thalamus; Single photon emission computed tomography

* Division of Nuclear Medicine, Hospital of the University of Pennsylvania, 110 Donner Building, 3400 Spruce Street, Philadelphia, PA 19104, USA. Tel.: +1-215-662-3014; fax: +1-215-349-5843.
E-mail address: newberg@oasis.rad.upenn.edu (A. Newberg).

1. Introduction

Meditation, in general, is a complex neurocognitive task that is often associated with alterations in body physiology and psychological measures. Over the past 30 years, a number of studies have explored the physiological correlates of different types of meditation. It is important to note here that meditation refers to a large variety of practices that range from purely relaxation-based to those performed with the goal of attaining powerful spiritual experiences. This variation, in itself, makes the study of such practices difficult. However, we have tried to find similarities among these practices, and feel that enough prior studies have demonstrated changes associated with these practices that it seems worthwhile to continue to explore them. Several studies have shown that meditation and related practices are associated with changes in the brain's electrical activity as observed on electroencephalography (EEG; Anand et al., 1961; Banquet, 1972; Corby et al., 1978; Benson et al., 1990). In particular, increased alpha-wave activity over the frontal regions of the brain has been observed during meditation and different EEG patterns may be associated with the relative strength of the experience. Other studies have measured different physiological changes associated with meditation including changes in autonomic nervous system activity such as those related to heart rate and blood pressure, and changes in cortisol levels (Jevning et al., 1992; Kesterson, 1989; Sudsuang et al., 1991).

Despite the availability of functional imaging techniques such as positron emission tomography (PET), single photon emission computed tomography (SPECT), and functional magnetic resonance imaging (fMRI), we are aware of only three reports utilizing neuroimaging techniques to study subjects practicing meditation. In these studies, neuroimaging was utilized to measure changes in cerebral function in subjects undergoing meditative relaxation techniques (Herzog et al., 1990; Lou et al., 1999; Lazar et al., 2000). Because there are many different types of meditation, it is important to evaluate and compare changes associated with different types of meditation to help elucidate the physiological mechanisms underlying the effects of meditation.

In this study, we present the ^{99m}Tc-HMPAO (hexamethyl propyleneamine oxime) SPECT data from eight practitioners of a form of Tibetan Buddhist meditation, performed specifically for spiritual, not-health-related, purposes. In this form of meditation, practitioners initially focus their attention on a visualized image and maintain that focus with increasing intensity. The 'peak' experience of their meditation is described as a sense of absorption into the visualized image associated with clarity of thought and a loss of the usual sense of space and time. We selected practitioners of this type of meditation because of their ability to reproduce the meditative experience despite being in the laboratory setting. The SPECT imaging technique used in this study measures regional cerebral blood flow (rCBF), which correlates closely with cerebral activity. Thus, this technique allowed for a comparison between the rCBF at baseline and during meditation.

We would like to emphasize that SPECT imaging and the methodology described below were chosen over other imaging techniques for several important practical reasons. Functional magnetic resonance imaging, while having improved resolution over SPECT and the ability of immediate anatomic correlation, would be very difficult to utilize for the study of meditation because of the noise from the machine. In fact, we attempted the use of fMRI with our initial subject in order to determine feasibility, but the subject found it extremely difficult to carry out the meditation practice. While PET imaging also provides better resolution than SPECT, our goal was to make the environment as distraction free as possible to maximize the chances of having as strong a meditative experience as possible. In order to achieve this goal, and because of our large research and clinical service, these scans were all performed after hours when fluorodeoxyglucose was no longer available. Thus, while PET and fMRI offer certain technical advantages, SPECT appeared to provide the best option for this initial study of meditation.

With regards to specific areas of the brain that might be involved during meditation, we

elaborated several hypotheses that would be the focus of this study. (1) Several investigators, including our group, have postulated increased activity in the frontal lobes, and in particular the prefrontal cortex, during meditation. This notion is based, in part, on the above-mentioned EEG studies on meditation as well as previous studies which have found increased frontal activity during attention-focusing tasks (Mizuki, 1983; Frith et al., 1991; Pardo et al., 1991). (2) Meditation is also associated with alterations in the subjective experience of space and time. We have postulated that there should be decreased activity in the superior parietal lobe since studies have shown this area to be involved with visual–spatial and temporal processing as well as body orientation (Lynch, 1980; Joseph, 1996). Furthermore, studies of spatial attention have demonstrated increased activity in the frontal lobes with relative decreased activity in the association areas. Thus, there should be a correlation between relative increases in the frontal lobes and relative decreases in the superior parietal lobes (Frith et al., 1991). (3) Meditation subjects often describe decreased sensory awareness and decreased motor activity, and we therefore predicted a decrease in the activity in the sensorimotor area. (4) There may be changes in the midbrain related to autonomic changes associated with meditation (Jevning et al., 1992; Sudsuang et al., 1991). (5) We expected relatively little change in the cerebellum, the superior frontal cortex, and the occipital lobes since no studies had implicated these areas as involved in meditation.

We also considered the possibility that there may be baseline differences in rCBF between subjects who practice meditation and those without such experience. In order to test this hypothesis, baseline rCBF in the meditation subjects was compared to that in a group of control subjects who were recruited for other, unrelated studies.

2. Methods

2.1. Subjects and imaging acquisition

Eight subjects with no history or clinical evidence of medical, neuropsychological, or drug abuse that would potentially alter CBF, were recruited to participate in this study. Four were women and four were men with ages ranging from 38 to 52 years with a mean age of 45 years. Each subject described himself or herself as a practicing Tibetan Buddhist meditator with more than 15 years of experience, usually including several three-month retreats and a yearly one-month retreat. They have meditated approximately 1 h per day, and at least five days a week. On the day of the study, after obtaining informed consent (approved by the Human Institutional Review Board with the study protocol), a room was set up in the hospital to function as a meditation room. Subjects were allowed to use incense throughout the baseline and meditation scans. Approximately 20 min prior to the baseline scan, an intravenous canula (IV) was placed in one arm. The subjects reported minimal discomfort from the IV that resolved prior to initiating the remainder of the study. Subjects were instructed to rest in the room with their eyes closed and ears unoccluded for 5–10 min at which time they were injected through the IV with 7 mCi of ^{99m}Tc-HMPAO (Amersham International, Arlington Heights, IL, prepared as specified by the manufacturer). Thirty minutes following the injection, the subject was scanned for 45 min in a Picker–Prism (Picker Inc., Cleveland, OH) triple-headed rotating gamma camera using high-resolution fanbeam collimators. Projection images were obtained at three-degree angle intervals on a 128 × 128 matrix (pixel size 3.56 × 3.56 mm) over 360° by rotating each head 120°. These SPECT images were reconstructed in the transaxial, coronal, and sagittal planes using filtered backprojection, followed by a Weiner post filter and 1st order Chang attenuation correction. The reconstructed slice thickness was 4 mm with a spatial resolution of 8–10 mm.

Nine control subjects, recruited as a group of healthy controls for other activation studies, had undergone a baseline SPECT imaging scan similar to those described above. The baseline scans of the control subjects were then compared to the baseline scans of the meditators to assess baseline changes in the meditation subjects.

Following this 'baseline' scan, the subject returned to the room for meditation. They were allowed to sit comfortably on pillows to maintain their usual posture during the meditation. They were also allowed to utilize several meditation books initially, although they had their eyes closed (their ears were also unoccluded) during approximately the final 30 min of the meditation, including during the time of the second injection of HMPAO. Outside noise was kept to a minimum and the door of the room was closed during the meditation. The subject meditated for approximately 1 h at which time the subject provided a 'signal', observable to the investigators, that was incorporated as part of the meditation practice (because of the use of this signal that marked when the subjects were about to begin the most intense part of the meditation, we felt that concurrent measurement using electroencephalography to determine if subjects were asleep was not necessary). Several minutes after this signal, the subject was injected with 25 mCi of ^{99m}Tc-HMPAO though the IV from outside the meditation room (in order not to disturb the subject) while he/she continued to meditate for approximately another 10–15 min, maintaining the same intensity of meditation. The meditation session was ended, and 30 min after this injection the subject was then scanned ('meditation' scan) for 30 min using the same imaging parameters as for the baseline study.

2.2. Image analysis and statistics

Several different statistical approaches were used in order to answer the questions raised by our hypotheses.

2.2.1. Region of interest analysis

The images of the baseline and meditation scans were reconstructed and resliced, using an oblique reformatting program, according to the anterior–posterior commissure line so that the final two sets were at comparable anatomical sites for the analysis. A previously validated template methodology consisting of regions of interest (ROI) corresponding to the major cortical and subcortical structures was placed over the baseline scan (Resnick et al., 1993). For the purposes of this study, we examined the rCBF as measured in only a selected number of ROIs, which was hypothesis driven. The ROIs examined were the inferior frontal, superior frontal, dorsolateral pre-frontal, orbitofrontal, dorsal medial cortex, inferior temporal, superior parietal, inferior parietal, occipital, and sensorimotor areas, as well as the caudate, thalami, midbrain, cerebellum, and cingulate gyrus. Each ROI (which is small and therefore represents a 'punch biopsy' of any given area) had its placement adjusted manually in order to achieve the best fit according to the atlas. The ROIs were then copied directly onto the meditation scan. This was possible because the images were already resliced into the same planes as described above. The count values for the meditation scans were obtained by determining the number of counts in each ROI on the meditation scan and subtracting the number of counts in the same ROI on the baseline scan which were decay corrected to the midpoint of the two scans. Counts per pixel in each ROI were obtained for both the baseline and meditation scans and normalized to the whole brain activity. This provides an rCBF ratio for each ROI compared to the whole brain. A percentage change was calculated using the equation:

$$\%\ \text{Change} = \frac{(\text{Meditation} - \text{Baseline})}{1/2\ \times(\text{Meditation} + \text{Baseline})} \times 100.$$

A laterality index (LI) was also calculated to determine the relative activity of homologous regions in the left and right hemisphere using the following equation:

$$\text{LI} = \frac{(\text{Right} - \text{Left})}{1/2\ \times(\text{Right} + \text{Left})} \times 100.$$

A mixed model analysis was used to compare baseline and meditation rCBF using data from both the left and right brain hemispheres. The mixed model was necessary to adjust for the correlation between multiple observations collected on each subject (SAS Institute, Inc.). These results are presented in Table 1 and discussed in

Table 1
Assessing the difference between baseline and meditation rCBF based on ROI analysis

Part of the brain	*P*-value	Baseline mean	Meditation mean	Percent change	Standard deviation
Anterior cingulate	0.0074	1.25	1.34	7.2	0.08
Cingulate body	0.0001	0.91	1.14	25.3	0.13
DLPFC	0.0001	1.31	1.45	10.7	0.08
Inferior frontal	0.0025	1.25	1.36	8.8	0.09
Midbrain	0.0166	1.16	1.29	11.2	0.14
Orbital frontal cortex	0.0075	0.97	1.22	25.8	0.24
Posterior cingulate	0.0114	1.19	1.29	8.4	0.09
Sensorimotor	0.0017	1.19	1.26	5.9	0.06
Thalamus	0.0114	1.40	1.60	14.3	0.21
Dorsomedial cortex	0.0154	1.26	1.31	4.0	0.06
Superior parietal	0.1715	1.18	1.12	−5.0	0.11
Caudate	0.5743	1.29	1.32	2.3	0.13
Cerebellum	0.2534	1.23	1.25	1.6	0.04
Inferior temporal	0.2486	1.29	1.34	3.9	0.13
Superior frontal	0.7484	1.18	1.17	−0.9	0.09

the results section. An analysis of the laterality indices for each homologous pair of ROIs in the baseline and meditation scans was performed using a two-tailed Student's *t*-test.

2.2.2. Statistical parametric mapping (SPM)

The image volumes of transverse slices were made compatible with SPM by creation of usable headers for the images. For each image, a file was created that contained data on image size, number of slices, pixel depth, maximal pixel value, and voxel size. All slices of a brain image were sampled and averaged to arrive at a mean pixel intensity for that image. The intensity threshold was set at 60% of the whole brain value. The images were spatially normalized in SPM to a standardized stereotactic space based on the atlas of Talairach and Tournoux (1988). The normalization process included further isotropic smoothing to a total of 12 mm. The significance threshold for increased activity was set at $P < 0.01$, and that for decreased activity was set at $P < 0.001$ ($Z > 3.20$) comparing the expected and observed number of pixels above the threshold (Friston et al., 1995). The location and peaks of significant increases and decreases were obtained. The cerebral structures were identified by their Talairach co-ordinates.

2.2.3. Correlations between brain structures

Pearson correlations were generated to assess the association between changes in rCBF values in different regions. Significance tests for the correlations were limited to the structures of the posterior superior parietal lobe, dorsolateral prefrontal cortex, thalamus, midbrain, and sensorimotor cortex since these were the areas that would most likely interact with each other during the task of meditation. Because of the small sample size, all results were confirmed using Spearman correlations. The results of both methods were similar, so only Pearson correlations will be presented.

2.2.4. Baseline changes in meditators compared to controls

Using a two-tailed Student's *t*-test, the rCBF values at baseline for the meditators were compared to those of a group of healthy control subjects, involved in other SPECT studies, who underwent a similar baseline imaging protocol.

3. Results

The results of the mixed model analysis from this study are shown in Table 1 (see also Fig. 1).

Relative CBF increases were observed in the inferior and orbital frontal cortices, the dorsolateral prefrontal cortices, the sensorimotor cortices, the dorsomedial cortices, the midbrain, the cingulate gyri, and the thalami. The other regions showed no significant changes in activity. The laterality index was not significantly changed in any of the ROIs when meditation scans were compared to the baseline.

The results from the SPM analysis are shown in Tables 2 and 3. Increases were only found in the right thalamus and decreases in the superior parietal lobe, the right lateral temporal and the eft inferior temporal lobes. While these findings corroborate some of the ROI results, other areas observed to be increased on the ROI analysis were not observed to be significantly different on the SPM analysis. This may be due to the over-conservative nature of SPM and the relatively small changes we were observing in the meditation state. Furthermore, the small number of subjects lead to a false-negative result with SPM analysis. We did not observe a significant change in the inferior temporal lobes in the ROI analysis, but this may be due to the relatively large area that was used for this particular region.

There were several significant correlations between the change in activity in certain structures. The change in activity in the left dorsolateral prefrontal cortex (DLPFC) correlated positively with the change in activity in the left thalamus ($r = 0.71$, $P = 0.049$). The change in activity in the right DLPFC correlated positively with the change in activity in the right thalamus ($r = 0.71$, $P = 0.05$). The change in activity in the left DLPFC correlated negatively with the change in activity in the left superior parietal lobe ($r = 0.76$, $P = 0.03$).

There were no significant differences observed between the baseline scans of the meditators and control subjects. The laterality index was calculated for several regions including the frontal cortices, thalami, and superior parietal lobes. The only notable distinction between the meditation and control subjects was observed in the thalami. In the thalami, the meditation group had a baseline laterality index of 9.97, which was significantly different compared to the baseline laterality score of the control group (3.78, $P = 0.03$). No other significant differences were observed in either the laterality index or rCBF values between the meditation and control group. Interestingly, the laterality index in the meditation group moved toward the value of the control group on the meditation scans. However, this change in laterality index was not statistically significant.

Table 2
Location and peaks of significant ($P < 0.01$) increase in regional cerebral blood flow during meditation

Structure	Co-ordinates			
	x	*y*	*z*	*z* score
R thalamus	4	−8	6	3.64
R thalamus	10	−24	2	3.39

4. Discussion

Regarding our initial hypotheses, the first was that we expected to observe an increased level of activity in the frontal cortices, particularly the prefrontal areas. Several studies have examined the effects of the complex neurocognitive task of meditation on brain activity. Most of these studies involved electroencephalographic (EEG) measurements during meditation in comparison to baseline (Corby et al., 1978; Banquet, 1972). Proficient practitioners usually have been shown to have increased alpha and theta amplitudes, particularly over the frontal lobes, compared to baseline (Hirai, 1974). These changes were also associated with increased autonomic activation. One

Table 3
Location and peaks of significant ($P < 0.001$) decrease in regional cerebral blood flow during meditation

Structure	Coordinates			
	x	*y*	*z*	*z* score
R superior parietal	18	−68	56	3.59
L superior parietal	−16	−58	50	3.50
R lateral temporal	62	−30	12	3.39
L inferior temporal	−46	−72	−2	3.29

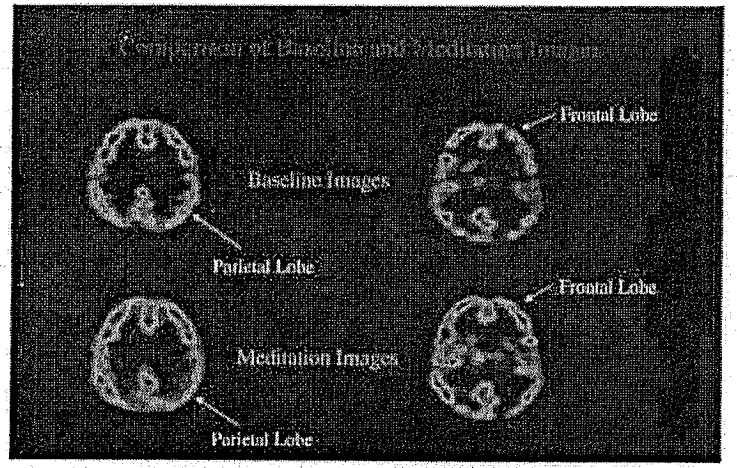

Fig. 1. This figure shows two transaxial slices of the baseline state (top) and the meditation state (bottom) with rCBF represented as red > yellow > green > blue. These images demonstrate increased rCBF during meditation in the frontal lobes bilaterally. Also, there is a marked decrease in blood flow in the left superior parietal area (as indicated by the arrow) during meditation.

report utilizing rheoencephalography (a form of electrical impedance plethysmography) to measure changes in cerebral blood flow during meditation found relative increases in the frontal cortex and occipital cortex (Jevning et al., 1996). However, rheoencephalography is unable to measure more detailed regions of the brain as can be accomplished with SPECT.

We found only a few reports in the literature utilizing functional neuroimaging techniques to study changes in the brain during meditation. One study used [F18] fluorodeoxyglucose PET to measure regional glucose metabolism in eight subjects undergoing Yoga meditative relaxation (Herzog et al., 1990–1991). In this study there was a significant increase in the frontal/occipital ratio of cerebral metabolism. Specifically, there was only a mild increase in the frontal lobe, but marked decreases in metabolism in the occipital and superior parietal lobes. More recently, PET imaging has been utilized to measure cerebral blood flow changes in nine subjects performing Yoga relaxation techniques (Lou et al., 1999). That study did not report increases in the frontal areas, although the subjects were practicing a 'passive' type of meditation such that they were listening to a tape guiding them through various meditation tasks. Also, neither of these PET studies reported correlations between the activity in various brain structures.

In our reported SPECT study, the results support the hypothesis that meditation is associated with increased activity in the frontal areas. The subjects in this study had mildly increased activity in the prefrontal and orbital frontal cortices on ROI analysis, which is similar to the finding of Herzog et al. (1990) and Lazar et al. (2000). Such a finding is also consistent with those from other

studies which have shown increased activity in the prefrontal cortex associated with attention-focusing tasks (Frith et al., 1991; Pardo et al., 1991). The increased activity observed during meditation in our study and others is most likely related to the active process of meditation in which subjects willfully concentrate upon their meditation. The study by Lou et al. (1999) did not demonstrate such findings. However, one of the important distinctions in that study was that subjects listened to a tape that guided them through the meditation. Thus, the participants were much more passive than the subjects in our study. Studies which have shown increased activity in the frontal lobes during concentration tasks would suggest that the more a person actively focuses attention, the more likely there is to be an increase in the frontal lobe activity. Thus, the increased frontal activity in the SPECT study presented here is consistent with the active attention-focusing component of this type of active meditation.

Our second hypothesis was that there would be a relative decrease in activity of the superior parietal areas associated with the sense of an altered experience of space during meditation (d'Aquili and Newberg, 1993). While we did not find a significant decrease in the superior parietal lobes on ROI analysis, there was an overall trend in this direction and we did find decreased activity on the SPM analysis. More importantly, the increased activity in the left prefrontal cortex correlated significantly with the decreased activity in the left superior parietal lobe. Several studies have shown that there are alterations in activity in the superior parietal lobe, particularly in association with increased activity in the prefrontal cortex, in subjects performing visual–spatial tasks (Cohen et al., 1996; D'Esposito et al., 1998). Thus, these studies not only suggest that the superior parietal lobe is associated with spatial processing, but that it interacts with the prefrontal cortex during such processing. The correlation between the change in activity of the prefrontal cortex and the superior parietal lobe in this SPECT study suggests that such an interaction may also occur during meditation. However, more detailed studies will be necessary to corroborate and expand such findings.

Our third hypothesis was that there would be a relative decrease in activity of the sensorimotor areas since meditation has the specific goal of reducing external distraction including sensory stimuli and body movement. Our findings demonstrated an increased level of activity in these areas, which appears to contradict this hypothesis. It is possible that while extraneous sensory and motor activity may be diminished, there is still a significant degree of motor activity required to maintain the subject's posture and there may at least be some form of visual input from the internal images generated during this type of meditation. This, of course, is speculation, and future studies are necessary to explore the relationship of the sensorimotor cortex to meditative practices.

Meditation has frequently been associated with alterations in autonomic nervous system activity. Studies of meditating subjects have often reported decreases in blood pressure, heart rate, and changes in galvanic skin responses (Jevning et al., 1992; Sudsuang et al., 1991). We and others have proposed that both sympathetic and parasympathetic activity may be increased during the meditation process (d'Aquili and Newberg, 1993; Peng et al., 1999). The increased activity in the midbrain observed in this study may be associated with alterations in autonomic activity during this type of meditation. However, such conclusions regarding the basis of increased midbrain activity require further studies for clarification, especially since we did not specifically measure autonomic function.

We had also hypothesized that we would not see significant changes in the cerebellum, superior frontal, or occipital areas since these do not contribute functions that might be expected to be related to the practice of meditation. However, one interesting finding that was not expected was that there was significantly increased activity in the thalamus. This may reflect its function as a major cortical and cortical–subcortical relay. Thalamic activity might be important for the overall complex processes we believe to be associated

with meditation, which includes both cognitive and affective responses.

Finally, that the meditation group had a significantly different thalamic laterality index at baseline compared to controls supports the notion that meditating subjects may have changes in their brain at rest. This is an interesting finding that needs to be explored by examining a larger sample of subjects. We only examined eight laterality scores and for this reason did not perform a Bonferroni correction; however, only the thalamic laterality was found to be significantly different. Moreover, if baseline differences between the two groups are substantiated in future studies, the question arises as to whether this alteration in function is related to many years of meditation practice, or if these subjects were born with such a distinction which might have predisposed them to adopt meditation during their lives. Answers to such questions remain purely speculative at this time.

We present this preliminary study to illustrate several points regarding the measurement of rCBF during meditation. We have shown a simple method by which HMPAO SPECT can be used to detect changes in rCBF during Tibetan Buddhist meditation. Also, this type of study can be applied to other forms of meditation (i.e. passive forms) to explore whether different types of meditation are associated with different neurophysiological correlates.

Potential confounding problems with this study include the fact that the subjective sense during the meditation is difficult to measure. We had subjects fill out questionnaires after the study, but found that the subjective responses were impossible to quantitate or analyze in a useful manner. However, all subjects felt that they had had an adequate meditation session. Other physiological measures, while potentially providing additional interesting information, would also not have been able to confirm the specific subjective state, such as the depth of the meditation, of each subject during the study. We also did not feel that EEG was necessary to exclude the possibility that the subject had fallen asleep because required hand signals demonstrated that subjects were awake. However, now that we have shown evidence for changes occurring during meditation, future studies will need to explore how cerebral activity as measured by EEG patterns and neuroimaging studies correlate with each other as well as physiological measures such as blood pressure, heart rate, and respiratory rate. This study also measured rCBF at a single point during meditation, which is obviously a lengthy process that requires time for various cognitive and affective responses to occur. Thus, the images are taken only during the assumed peak of meditation and may, in fact, reflect activity during some other component of the meditation. The study has a limited number of meditation subjects since it is most difficult to find highly experienced meditators. While this complicates the statistical analysis, the number of subjects is comparable to that in previous studies of other types of meditation and was enough to reveal statistically meaningful results. Finally, while fMRI and PET have taken the lead in brain activation studies and both methods provide technical advantages over SPECT, meditation presents the particular problem of requiring a quiet, distraction-free environment. To provide this, fMRI would be too noisy and fluorodeoxyglucose for PET studies is often not available during the times that these studies are best performed. However, future efforts to make such techniques more amenable to the study of meditation may be fruitful in helping to better define the underlying physiological basis of such practices.

5. Conclusion

The results from this initial study have begun to elucidate the neurophysiological correlates of complex cognitive functions such as meditation. The findings also support our hypotheses that meditation is associated with increased activity in the frontal lobes and that such activity is correlated with decreased activity in the posterior parietal lobes. These two findings, respectively, may be attributable to the increased attention of subjects and the experience of alterations of the sense of space. That there were also changes in activity in the thalami, sensorimotor cortex, and midbrain suggests that there is an intricate level

of central nervous system interactions during this type of meditative practice. Future imaging research should explore the cerebral correlates of meditation in a larger number of subjects as well as incorporate other physiological and neurophysiological measures. Such studies will be essential to elucidate the basic mechanisms that underlie subjective and clinical observations during the complex neurocognitive task of meditation.

References

Anand, B.K., China, G.S., Singh, B., 1961. Some aspects of electroencephalographic studies on yogis. Electroencephalogry and Clinical Neurophysiology 13, 452–456.

Banquet, J.P., 1972. EEG and meditation. Electroencephalogry and Clinical Neurophysiology 33, 454.

Benson, H., Malhotra, M.S., Goldman, R.F., Jacobs, G.D., Hopkins, P.J., 1990. Three case reports of the metabolic and electroencephalographic changes during advanced Buddhist meditation techniques. Behavioral Medicine 16, 90–95.

Cohen, M.S., Kosslyn, S.M., Breiter, H.C., DiGirolamo, G.J., Thompson, W.L., Anderson, A.K., Bookheimer, S.Y., Rosen, B.R., Belliveau, J.W., 1996. Changes in cortical activity during mental rotation: a mapping study using functional MRI. Brain 119, 89–100.

Corby, J.C., Roth, W.T., Zarcone, V.P., Kopell, B.S., 1978. Psychophysiological correlates of the practice of Tantric Yoga meditation. Archives of General Psychiatry 35, 571–577.

d'Aquili, E.G., Newberg, A.B., 1993. Religious and mystical states: a neuropsychological model. Zygon 28, 177–200.

D'Esposito, M., Aguirre, G.K., Zarahn, E., Ballard, D., Shin, R.K., Lease, J., 1998. Functional MRI studies of spatial and non-spatial working memory. Cognitive Brain Research 7, 1–13.

Friston, K.J., Holmes, A.P., Worsley, K.J., Poline, J.P., Frith, C.D., Frackowiak, R.S.J., 1995. Statistical parametric maps in functional imaging: a general linear approach. Human Brain Mapping 2, 189–210.

Frith, C.D., Friston, K., Liddle, P.F., Frackowiak, R.S.J., 1991. Willed action and the prefrontal cortex in man. A study with PET. Proceedings of the Royal Society of London 244, 241–246.

Herzog, H., Lele, V.R., Kuwert, T., Langen, K.-J., Kops, E.R., Feinendegen, L.E., 1990. Changed pattern of regional glucose metabolism during Yoga meditative relaxation. Neuropsychobiology 23, 182–187.

Hirai, T., 1974. Psychophysiology of Zen. Igaku Shoin, Tokyo.

Jevning, R., Anand, R., Biedebach, M., Fernando, G., 1996. Effects of regional cerebral blood flow of transcendental meditation. Physiology and Behavior 59, 399–402.

Jevning, R., Wallace, R.K., Beidebach, M., 1992. The physiology of meditation: a review. A wakeful hypometabolic integrated response. Neuroscience and Biobehavioral Reviews 16, 415–424.

Joseph, R., 1996. Neuropsychology, Neuropsychiatry, and Behavioral Neurology. Plenum, New York.

Kesterson, J., 1989. Metabolic rate, respiratory exchange ratio and apnea during meditation. American Journal of Physiology R256, 632–638.

Lazar, S.W., Bush, G., Gollub, R.L., Fricchione, G.L., Khalsa, G., Benson, H., 2000. Functional brain mapping of the relaxation response and meditation. Neuroreport 11, 1581–1585.

Lou, H.C., Kjaer, T.W., Friberg, L., Wildschiodtz, G., Holm, S., Nowak, M., 1999. A ^{15}O-H_2O PET study of meditation and the resting state of normal consciousness. Human Brain Mapping 7, 98–105.

Lynch, J.C., 1980. The functional organization of posterior parietal association cortex. Behavioral Brain Sciences 3, 485–499.

Mizuki, Y., 1983. The relationship between the appearance of frontal midline theta activity (Fm) and memory function. Electroencephalography and Clinical Neurophysiology: Japan EEG/EMG Society Proceedings 56, 56.

Pardo, J.V., Fox, P.T., Raichle, M.E., 1991. Localization of a human system for sustained attention by positron emission tomography. Nature 349, 61–64.

Peng, C.K., Mietus, J.E., Liu, Y., Khalsa, G., Douglas, P.S., Benson, H., Goldberger, A.L., 1999. Exaggerated heart rate oscillations during two meditation techniques. International Journal of Cardiology 70, 101–107.

Resnick, S.M., Karp, J.S., Tretsky, B.I., Gur, R.E., 1993. Comparison of anatomically defined vs. physiologically based regional localization: effects on PET–FDG quantitation. Journal of Nuclear Medicine 34, 201–208.

SAS Institute, Inc., SAS/STAT Software: Changes and Enhancements Through Release 6.12, Cary, NC: SAS Institute Inc., p. 1167.

Sudsuang, R., Chentanez, V., Veluvan, K., 1991. Effect of Buddhist meditation on serum cortisol and total protein levels, blood pressure, pulse rate, lung volume and reaction time. Physiology and Behavior 50, 543–548.

Talairach, J.A., Tournoux, P., 1988. Stereotactic Coplanar Atlas of the Human Brain. Thieme, Stuttgart.