

University of Pennsylvania School of Dental Medicine

**A Multivariate Analysis of the Outcome of Endodontic
Microsurgery Using MTA or ERRM as Root-End Filling
Material: A Randomized Clinical Trial with Cone-Beam
Cone Beam Computed Tomography Evaluation**

THESIS

Dr. Chafic Safi
07/08/2015

Bekir Karabucak, DMD, MSc
Major Thesis Advisor
Interim Chair and Program Director
Department of Endodontics

Syngcuk Kim, DDS, PhD, MD (hon)
Louis I Grossman Professor
Associate Dean for Global Affairs
Department of Endodontics

Jonathan Korostoff, DMD, PhD
Director of Master of Science in Oral
Biology Program
Associate Professor
Department of Periodontics

Denis F. Kinane, BDS, PhD
Morton Amsterdam Dean
Professor
Department of Pathology
Department of Periodontics



University of Pennsylvania Dental Medicine

THESIS

Presented to the Faculty of Penn Dental Medicine in Fulfillment of the
Requirements for the Degree of Master of Science in Oral Biology

DR. DENIS KINANE
HORTON AUSTEROM DEAN
DEPARTMENT OF PERIODONTICS

DR. BEKIR KARABUCAK
INTERIM CHAIR & PROGRAM DIRECTOR
DEPARTMENT OF ENDODONTICS

DR. SUNGCUK KIM
ASSOCIATE DEAN OF GLOBAL AFFAIRS
LOUIS I. GROSSMAN PROFESSOR
DEPARTMENT OF ENDODONTICS

DR. JONATHAN KOROSTOFF
HSOB DIRECTOR
PROFESSOR
DEPARTMENT OF PERIODONTICS

ACKNOWLEDGEMENTS

I would like to thank Dr. Bekir Karabucak, my principal investigator, for having allowed me the opportunity to participate in this study and further expand my horizons, and for his guidance, input and support throughout the whole process and my whole residency.

Many thanks to Dr. Syngcuk Kim for following up with me on a regular basis, and having given me the opportunity to be part of the department of Endodontics and to learn a tremendous amount about this discipline.

I would like to thank Dr. Jonathan Korostoff for having accepted to be part of my thesis committee and for always being there to answer my questions, and for guiding me through the process of writing my thesis.

A big thank you to our dean, Dr. Denis Kinane, for kindly accepting to be a part of my thesis committee, and for his constant encouragement and motivation.

I want to express my gratitude to Dr. Meetu Kohli and Dr. Sam Kratchman for all the time they devoted to guiding and counseling me throughout the whole process of the study, and for their tremendous help in evaluating the radiographs. Their constant input has been crucial and essential to finalize my project.

I owe special thanks to Christel Chehoud for accepting to assist me in the statistical analysis of the results despite her own heavy course load.

I would also like to thank my colleagues (Dr. Guillaume Jouanny, Dr. Nathan Hinckley, Dr. Patrick Haffey, Dr. Saleh Rajaeian, Dr. Joon Park, Dr. Kosuke Tanaka, and Dr. Mohammed Al-Harbi) for their support during all these years.

Finally, I would like to thank my family for their unconditional love and support throughout my life. I also would like to extend my gratitude to my fiancée Dr. Sandrine Barakat for her patience and support all the time throughout dental school and residency.

To all those people, thank you very much.

TABLE OF CONTENTS

Literature Review	4-17
Reference	18-21
Aim	22
Abstract	22-23
Paper	24-55
References	55-59
Annex	60-75

Literature Review

Tooth retention amongst older adults has been increasing steadily over the past several decades. This is a result of substantial improvements including community water fluoridation and fluoride toothpaste, changing patient and provider attitudes, improved oral hygiene, regular use of dental services and advancements in dental technologies and treatment modalities (1,2).

The discipline of Endodontics itself has come a long way, surviving many myths such as the “focal infection theory”, and still contributes today to helping patients save their natural dentition. With a rise in patient expectations, there was an increasing pressure to offer various treatment modalities with predictable outcomes. During the last 15 years, Endodontics witnessed a wave of advancements notably with the introduction of magnification and illumination via the operating microscope (OM), rotary instrumentation, electronic apex locators, new irrigation techniques, ultrasonic tips (US), three-dimensional imaging and a new family of filling material called bioceramics (BC).

Although the general success rate of Non Surgical Endodontic Therapy (NSRCT) has remained within the same range of 86%-96%, the new available technology and material allows us to achieve this rate more predictably and with fewer visits (3).

The big difference in terms of predictability and outcome with the advent of the new advancements comes from apical surgery. Traditional apical surgery (TAS) outcome ranged between 19%-59%. In contrast, endodontic microsurgery (EMS) outcome studies indicate a success rate of 94%-96%(4).

Furthermore the introduction of cone beam computed tomography (CBCT) to Endodontics offers an in-depth view of the periradicular tissues compared to periapical radiographs (PA). This is especially beneficial when planning and assessing healing following EMS (5,6).

In the following sections, general differences between TAS and EMS, outcome assessment using PA and CBCT, as well as other variable affecting outcome of EMS will be discussed.

I. Traditional apical surgery VS Endodontic microsurgery (7)

TAS has always been perceived as a last resort to save a tooth. Technically, it is executed by using the conventional chair light system and regular magnifying loupes, in cases where the operator uses them. This lack of light and difficulty to visualize the site create a surgery where the operator estimates his fields of work, therefore resulting in large osteotomy sites of approximately 8-10mm. The root-end resection was performed using a conventional high-speed hand piece resulting in a beveled cut and exposing infected dentinal tubules attached to the root. The bevel cut also hindered the identification of missed canals. It was impossible to inspect the resected surface due to lack of instruments and techniques and thus isthmus identification was also impossible. Retro-preparing the root was seldom, and when performed was done using a round bur which was neither safe nor effective. Finally, amalgam was used as a filling material, however its cytotoxicity and poor sealing ability prevented regeneration of periapical tissues. Despite the introduction of several other materials to replace amalgam, such as intermediate restorative material (IRM/ L.D. Caulk Inc, Dentsply International Inc, Milford, DE) or Super-EBA

(Bosworth Company, Skokie, IL), none gained popularity. Overall, the outcome of TAS as described above ranged between 19.4%-57% over a period of 1 to 5 years.

The advent of EMS on the other hand offers a wide range of new instruments and techniques which make the procedure more pleasant to execute and more predictable. As its name implies, the usage of OM during EMS offers a new dimension of magnification and illumination allowing the operator to execute his work more precisely and to remove pathological lesions with increased acuity, thus minimizing tissue damage during the surgery. The OM also eliminates guesswork, allowing for a smaller osteotomy size of 3-4mm. Coupled with a surgical hand piece, the magnification and illumination offered by the OM also allow for a straight root-end resection. Methylene blue staining and micro mirrors provide a means in identifying missing canals and also offer a closer and clearer inspection of the resected surface in order to detect fractures and isthmuses. The retro-preparation in this case is done using US that can be bent and directed in the operator's most ergonomic way. This insures that a 3-4mm space preparation is always created inside the canal and in the tooth axis. As a retro-filling material, Mineral Trioxide Aggregates (MTA) (ProRootMTA, Dentsply Tulsa Dental, OK) was the first of its BC class to be introduced in EMS and quickly became the material of choice. In recent years, a new retro-filling material has been introduced to the BC family, EndoSequence Root Repair Material (ERRM) (Brasseler USA, Savannah, GA), and is quickly gaining popularity. Overall, the probability of success of EMS is 1.58 times the probability of success for TAS with an outcome range between 94%-96% over a period of 5 years (4).

Ia. Bioceramics: From Paris to Vietnam to Endodontics (8,9)

BC is a class of calcium-rich material designed to achieve a specific physiological behavior for use in repairing and reconstructing of internal organs. The first attempt to repair the human body with the use of "implanted" material dates back to the Egyptian and Greek civilizations. Little is known about the material used and their outcome.

The first BC that was widely tested was plaster of Paris. In 1892 Dreesman published the first report on the use of plaster of Paris to fill defects in bone. He described the results of clinical operative procedures on eight patients. In three of six patients, tuberculous cavities in bone were solidly filled with new bone. Calcium hydroxide was the next BC material investigated. Studies by Mitchell and Shankwalker in 1958 corroborate that calcium hydroxide, when implanted subcutaneously, stimulated the formation of what appeared to be immature bone.

By 1963, Oxide ceramics were being developed by impregnating a 48% porous aluminate ceramic with an epoxy resin. The resulting ceramic closely matched the physical properties of bone and was hence used in repairing bony defects. Oxide ceramics are today classified as inert BC meaning that they undergo little or no chemical change when exposed to physiological environment. Their main usage is in the fabrication of joint prostheses.

In 1971, tricalcium phosphate ceramics made their appearance. These types of ceramics were found to act as a scaffold for tissue ingrowth while undergoing resorption. Their usage as bone grafting material proved successful and more beneficial than inert BC. These are today classified as resorbable BC and their main

usage resides in treating maxillofacial defects.

Parallel to the development of resorbable BC, L.L. Hench in 1969 was prompted by a Vietnam US army colonel to create a material that would help his soldiers save their limbs after injury on the battlefield. In 1972, he formulated a specific glass composition with high calcium content that would form a bond with the surrounding living tissues and elicit specific physiological responses by forming a surface layer of apatite-like material. These types of ceramics are classified today as surface reactive BC or as bioglass and are mainly used in ossicular bone replacement and as coatings for orthopedic appliances.

By 1981, many types of bioglasses had been developed showing not only bone-bonding properties but also bonding to connective tissue. These materials are all based on Hench's original formulation.

In 1999, MTA, a revolutionary BC material was introduced into the field of Endodontics offering various clinical applications. By 2008, ERRM, another BC material was also introduced into endodontics offering the same clinical applications and much more.

Ib. Mineral Trioxide Aggregates VS EndoSequence Root Repair Material

MTA has been a revolutionary material in Endodontics. Since its introduction in the 1990s several studies have demonstrated its use in various clinical applications.

MTA has been extensively studied and is currently used for perforation repairs (10,11), apexifications (12,13), regenerative procedures (14), pulpotomies (15), pulp capping (16) and retro-filling material during EMS (17). Classified as calcium silicate cement, it is composed of purified Portland cement with some modifications.

Its main ingredients are tricalcium silicate, tricalcium oxide, tricalcium aluminate, silicate oxide, and bismuth oxide (18).

MTA has several desirable properties in terms of its biocompatibility (16), bioactivity (19), hydrophilicity (19), radiopacity (19), sealing ability (16) and low solubility (19). The most important of these properties in Endodontics are its biocompatibility and sealing ability. In addition to these two properties, MTA was observed to have a mitogenic and differentiation effect on human fibroblasts, cementoblasts, and mesenchymal stem cells (20). Histologically, MTA exhibits minimal inflammatory response with cementum-like tissue formation when used in the pulp space as part of pulp capping, pulpotomy, perforation repair, apexification, and root-end filling. MTA was also shown to bond to bone through formation of an apatite layer.

The sealing that is achieved is due to the material's expansion and contraction properties being very similar to dentin, which results in high resistance to both marginal leakage and to bacterial migration into the root canal system (19). A stable barrier to bacterial and fluid leakage is one of the key factors that facilitate clinical success. A very practical advantage of MTA is that, unlike many other dental materials, it sets in the moist environment that is omnipresent in dentistry. When in contact with moisture, the material's main component, which is calcium oxide, converts into calcium hydroxide resulting in a high pH microenvironment, which has beneficial antibacterial effects. Unlike calcium hydroxide, however, MTA has very low solubility and maintains its physical integrity after placement (21).

Despite its clinical efficacy, MTA's handling remains one of its biggest deterrents

because it needs to be mixed with water in order to form a colloidal gel, which can then be used for therapeutic purposes. The working time can range between 5 minutes and 165 minutes and it takes 15 minutes to 4 hours to set (18). Also there is a risk of staining dental tissues (22).

The need of a user-friendly material that does not stain teeth with the potential clinical applications similar to MTA lead the way to developing ERRM. This material like MTA is a hydrophilic calcium silicate cement but with different chemical composition. Its main ingredients are tricalcium silicates, calcium phosphate, zirconium dioxide, calcium hydroxide and tantalum oxide (18). It does not need any mixing, rather it comes in a ready-to-use preparation and is available as a putty consistency, as a fast-set paste, and as root canal sealer. Its working time is 30 minutes and its setting reaction starts as soon as it contacts moisture and can take 2-4 hours before completion (18). Many in-vitro studies have been performed in order to test ERRM's biological effects.

There are 3 studies that evaluate the sealing ability of ERRM. In 2011, using *E. Faecalis* bacterial leakage model, Nair observed that 66.7% of ERRM samples leaked compared to 55.3% of the MTA samples over a period of 7 days without having any statistical significance (23). These findings are in accordance with Leal who showed that glucose leakage was similar in both materials after allowing a setting time of 72 hours (24). However these results contrast with Hirschberg's 2013 findings (25). Using *E. Faecalis* and allowing the materials to set for 48 hours, Hirschberg found that ERRM sample leaked significantly more than MTA over a period of 28 days. This conflict of results is due to various experiment protocol.

Lovato & Sedgley assessed ERRM antimicrobial activity compared to that of MTA (26). To do so, they isolated *E. Faecalis* from infected root canals and prepared 10mL of bacterial suspension that they placed onto setting ERRM and MTA. Their colony-forming unit in ERRM and MTA samples were significantly lower than their positive control and there was no significant difference between the 2 materials.

In terms of cytotoxicity of ERRM, in vitro studies show conflicting conclusions. In 2010, Alanezi was able to prove that just like MTA, freshly mixed and 72hours set ERRM does not affect L929 mouse fibroblasts viability when cultured over a period of 3 days (27). Other authors came to the same conclusion when using MG-63 human osteoblastic-like cells and human dermal fibroblasts (28). On the other hand, some studies have reported lower viable cell count using ERRM. Damas found less human dermal fibroblasts in ERRM groups when compared to untreated control groups (29). However no difference was observed between ERRM and MTA. Using human gingival fibroblasts, Ma observed significantly more cytotoxicity in ERRM samples (30). A recent experiment in our endodontic department assessed the effects of ERRM and MTA on human bone marrow derived mesenchymal stem cells (HBMSC), periodontal ligament stem cells (PDLSC), and dental pulp stem cells (DPSC) (31). The results showed that ERRM stimulated dentinogenic, cementogenic, and osteogenic differentiation in odontogenic and osteogenic stem cells, in particular DPSC. PDLSC showed similar response to ERRM and MTA. However, less HBMSC osteoinduction was observed with ERRM when compared to MTA. Despite the different experimental setups, there seems to be enough evidence suggesting that MTA and ERRM are similar in terms of cytotoxicity.

Furthermore, the results from a pilot study submitted for publication and done in our endodontic department showed that ERRM causes significantly less staining to teeth when compared to MTA (32). In our study, ERRM in the form of putty and fast set paste was placed in the coronal third of extracted teeth. The color stability was evaluated and compared to white MTA, grey MTA, and a negative control using spectrophotometry. The results showed that ERRM products significantly caused less tooth discoloration when observed over a period of 6 month.

So far, most of the studies comparing MTA to ERRM in terms of biological effects were in-vitro studies. The department of Endodontics at University of Pennsylvania recently published an in-vivo experiment assessing not only some biological effects of ERRM but also assessing outcome when used as a retro-filling material and comparing it with MTA (33). In this study, Chen et al. performed EMS on beagle dogs using ERRM or MTA randomly. The healing was assessed 6 month following the procedure by way of PA, CBCT, micro computed tomography (CT), and histology. Healing on PA was established according to Rud et al and Molven et al. Healing on CBCT was assessed using several parameters:

- 1- Healing on resected root-end surface in mesio-distal (M-D) and bucco-lingual (B-L) sections
- 2- Healing of periapical area in M-D and B-L section
- 3- Healing of cortical plate in B-L section
- 4- Alignment of root-end filling
- 5- Length of root-end filling

Histologically, sections were scored depending on:

1. Degree of inflammation present
2. Amount of cementum-like tissue formed on root-end filling material surface
- 3- Amount of PDL-like tissue formed
- 4- Amount of new bone formation adjacent to root end
- 5- Absence or presence of cortical plate formation
- 6- Presence of bacteria in root canal

The radiographic analysis showed no difference in healing between the 2 materials when compared via PA. CBCT and CT assessment showed more healing in the ERRM group than in the MTA group. Moreover, healing on the resected root-end surface and healing in the periapical area on both B-L and M-D sections showed statistically better healing when using ERRM. Histologically, the authors found that ERRM is as biocompatible in-vivo as MTA and has as good of a sealing ability. However, ERRM induced more cementum-like and PDL-like tissue formation. Cortical plate formation was independent of material used.

Based on the above ERRM is a biocompatible material with good sealing and mitogenic properties. However, little is known about this material in patient clinical settings. Shinbori published a case series in 2015 reporting a 92.0% success rate of EMS when using ERRM as a retro-filling material (34). However, only PA evaluation was done and there was no comparison with MTA. They also found no prognostic factor having any significant effect on the outcome. Therefore we designed a randomized clinical trial (RCT) to investigate the outcome of EMS on PA and CBCT when using ERRM or MTA and to identify any potential prognostic factor.

II. Success evaluation: Periapical radiographs VS cone-beam computed tomography

Radiographic examination in Endodontics has always relied on PA. Whether for diagnostics, detection of apical pathology, treatment planning, or follow-up examination, endodontists always relied on traditional 2-dimensional radiographs. However there are many limitations associated with PA notably the anatomical noise due to the superimposition of the regional anatomy with dentoalveolar structures. Additionally, the projection of a 3-dimensional structure such as the dentoalveolar complex on to a 2-dimensional film creates geometric distortion, which then can mask important information such as bone defects. These issues can be overcome by the usage of CBCT.

CBCT is accomplished by using a rotating gantry to which an x-ray source and detector are fixed. The x-ray source and detector rotate around a fixed fulcrum within the region of interest (35). During the exposure sequence, hundreds of planar projection images are acquired providing 3-D radiographic images. According to the American Association of Endodontists (AAE), The usage of CBCT should have a net benefit to the a patient's management and should be limited to (6):

- 1- Identification of root canal system anomalies and determination of root curvature.
- 2- Diagnosis of periapical pathology when there are contradictory signs and/or symptoms.
- 3- Diagnosis of nonodontogenic pathology
- 4- Intra- or postoperative assessment of endodontic treatment complications, such

as overextended root canal obturation

5-Diagnosis and management of dentoalveolar trauma, especially root fractures, luxation and/or displacement of teeth, and alveolar fractures.

6- Localization and differentiation of external from internal root resorption, and the determination of appropriate treatment and prognosis.

7- Presurgical case planning to determine the exact location of root apices and to evaluate the proximity of adjacent anatomical structures.

Perhaps the most important advantage of CBCT pertinent to our study is that it enables the detection of radiolucencies before they are visualized on conventional radiographs. Lesions in the cortical bone can only be detected on PA when there is perforation of the bone cortex, erosion from the inner surface of the bone cortex, or extensive erosion or defects on the outer surface (35). Periapical lesions in cancellous bone cannot be detected on PA. CBCT, however, can reveal bone defects of the cancellous bone and cortical bone separately. In a 2009 study by Estrela, 1508 teeth from 888 patients were submitted to PA, panoramic, and CBCT radiographic imaging (36). Results showed that prevalence of apical periodontitis (AP) when using CBCT was 64% compared to 18% when using panoramic and 35 % when using PA. In another study by Paula Silva, the periapex of 83 treated and untreated roots of dogs' teeth was examined using PA, CBCT, and histology (37). The prevalence of AP detected was 71% thru PA and 84% thru CBCT. Overall, sensitivity was 0.77 and 0.91 for PR and CBCT, respectively making CBCT more sensitive in detecting AP. Low K. et. al. compared PA and CBCT for preoperative diagnosis in posterior maxillary teeth. 34% of the radiolucencies detected with CBCT were

missed with PA (38). Additional findings were seen significantly more frequently in CBCT compared with PA such as missed canals and sinus membrane thickening.

Thus, CBCT is a more sensitive diagnostic method than PA and will be used in our RCT in assessing outcome of EMS.

III. Other variables affecting outcome of Endodontic Microsurgery

Understanding prognostic predictors is critical when it comes to choosing between EMS or alternative treatment methods. Patient-related factors and tooth-related factors were investigated in various studies assessing any factor that may affect the outcome of EMS. In 2010 Barone examined the outcome of 134 teeth that underwent EMS. The follow-up period ranged from 4-10 years (39). Results showed that 74% of the teeth had healed and that there were 3 outcome predictors: age, preoperative root-filling length, and the size of the surgical crypt. Surprisingly patients older than 45 years old exhibited better healing than younger ones. Root-filling lengths were classified into adequate and inadequate, with adequate ones having superior healing. An operative crypt size of 10mm or less also exhibited better healing. However other factors such as lesion size, absence or presence of perforations, root-end filling depths, and post-operative restoration did not have significant influence on outcome. A meta-analysis published the same year also investigated EMS prognostic factors (40). A total of 38 articles were included and prognostic factors were divided into patient-related, tooth-related, and treatment related factors. With regard to patient-related factors such as age and sex, none was a significant predictor of outcome. With regard to tooth-related factors, maxillary and mandibular anterior teeth, absence of pre-operative signs and symptoms, and a

periapical lesion of 5mm or less were identified as predictors of healing. Treatment-related factors such as first-time surgeries, US retro-preparation, using an endoscope, and retro-filling with MTA were significant predictors of outcome. However none of the mentioned studies employed CBCT in order to investigate outcome predictors. Therefore our RCT will investigate the effect of prognostic factors using PA and CBCT as well.

VI. Levels of evidence of studies assessing Endodontic Microsurgery

When an endodontist offers EMS to his patients, his decision to do so should be based on studies with high levels of evidence. The most highly ranked level of evidence is shown by meta-analyses, followed by systematic reviews then RCT (41). In a recent meta-analysis, Setzer F. et al. reported a 94% weighted pooled success rate for EMS over a period of 6 month (4). However, of the EMS studies included all used MTA as a retro-filling material and none used ERRM. In fact, there are no high level of evidence studies available today that compare the performance of these 2 materials as retro-filling during EMS. Our study will investigate the clinical efficacy of ERRM and MTA when randomly assigned as retro-filling material during EMS.

Reference

1. U.S. Department of Health and Human Services. Oral Health in America: a Report of the Surgeon General. Rockville, Maryland: U.S. Department of Health and Human Services, National Institutes of Health, National Institute of Dental and Craniofacial Research, 2000.
2. Center for Disease Control and Prevention. Public health and aging: retention of natural teeth among older adults--United States, 2002. *Morb Mortal Wkly Rep.* 2003 Dec 52:1226-9.
3. Paredes-Vieyra J, Enriquez FJ . Success rate of single- versus two-visit root canal treatment of teeth with apical periodontitis: a randomized controlled trial. *J Endod.* 2012; 38 (9): 1164-9.
4. Setzer FC, Shah S, Kohli M, Karabucak B, Kim S. Outcome Of Endodontic Surgery: A Meta-Analysis Of The Literature - Part 1: Comparison Of Traditional Root- End Surgery And Endodontic Microsurgery. *J Endod.* 2000; 36 (11):1757-65.
5. Patel S, Durack C, Abella F, Roig M, Shemesh H, Lambrechts P, Lemberg K European Society of Endodontology Position Statement: The use of CBCT in Endodontics. *Int Endod J.* 2014; 47 (6):502-4.
6. American Association of Endodontists Position Statement (2010), Use of Cone- Beam-Computed Tomography in Endodontics, <http://www.aae.org/guidelines>.
7. Kim S, Kratchman. Modern endodontic surgery concepts and practice: a review. *J Endod.* 2006; 32 (7): 601–23.
8. Hulbert SF, Hench LL, Forbers D, Bowman LL. History of Bioceramics. *Ceramics Intl.* 1982; 8 (4):131-9.
9. Best SM, Porter AE, Thian ES, Huang J. Bioceramics: Past, present and for the future. *J Eur Cer Soc.* 2008; 28: 1319-27.
10. Mente J, Leo M, Panagidis D, et al. Treatment outcome of mineral trioxide aggregate: repair of root perforations-long-term results. *J Endod.* 2014;40(6):790-796.
11. Lee SJ, Monsef M, Torabinejad M. Sealing ability of mineral trioxide aggregate for repair of lateral root perforations. *J Endod.* 1993;19(11) 541-544.

12. Parirokh M, Torabinejad M. Mineral trioxide aggregate: a comprehensive literature review-Part III: clinical applications drawbacks, and mechanism of action. *J Endod.* 2010;36(3):400-413.
13. Witherspoon DE, Small JC, Regan JD, Nunn M. Retrospective analysis of open apex teeth obturated with mineral trioxide aggregate, *J Endod.* 2008;34(10):1171-1176.
14. Banchs F, Trope M. Revascularization of immature permanent teeth with apical periodontitis: new treatment protocol? *J Endod.* 2004;30(4):196-200.
15. Ford T, Torabinejad M, Abedi H, Bakland L, Kariyawasam S. Using mineral trioxide aggregate as a pulp-capping material. *J Am Dent Assoc.* 1996;127(10):1491.
15. Parirokh M, Torabinejad M. Mineral trioxide aggregate: a comprehensive literature review-Part III: clinical applications drawbacks, and mechanism of action. *J Endod.* 2010;36(3):400-413.
16. Bogen G, Kim JS, Bakland LK. Direct pulp capping with mineral trioxide aggregate: an observational study. *J Am Dent Assoc.* 2008;139(3):305-315.
17. Shabahang S, Torabinejad M, Boyne P, Abedi H, McMillan P. A comparative study of root-end induction using osteogenic protein-1, calcium hydroxide, and mineral trioxide aggregate in dogs. *J Endod.* 1999;25(1):1-5
16. Torabinejad M, Parirokh M. Mineral trioxide aggregate: a comprehensive literature review-Part II: leakage and biocompatibility investigations. *J Endod.* 2010;36(2):190-202.
17. Shabahang S, Torabinejad M, Boyne P, Abedi H, McMillan P. A comparative study of root-end induction using osteogenic protein-.1, calcium hydroxide, and mineral trioxide aggregate in dogs. *J Endod.* 1999;25(1):1-5.
18. Jefferies SR. Bioactive and biomimetic restorative materials: A comprehensive review. Part 1. *J Est Rest Dent.* 2014; 26(1):14-26
19. Parirokh M, Torabinejad M (2010) Mineral trioxide aggregate: a comprehensive literature review-Part I: chemical, physical, and antibacterial properties. *J Endod* 36:16-27.

20. Koh ET, McDonald F, Pitt-Ford TR, et al. Cellular response to mineral trioxide aggregate. *J Endod* 1998;24:5437
21. Duarte MA, Demarchi AC, Yamashita JC, et al. Ph and calcium ion release of 2 root-end filling materials. *Oral Surg Oral Med Oral Pathol Oral Radiol Endod*. 2003;95(3):345-347.
22. Dammaschke T, Gerth HU, Zuchner H, Schafer E. Chemical and physical surface and bulk material characterization of white ProRoot MTA and two Portland cements. *Dent Mater*. 2005;21(8):731-738.
23. Nair U, Ghattas S, Saber M, Natera M, Walker C, Pileggi R. A comparative evaluation of the sealing ability of 2 root-end filling materials: an in vitro leakage study using *Enterococcus faecalis*. *Oral Surg Oral Med Oral Pathol Oral Radiol Endod*. 2011 Aug1;112(2):e74–7.
24. Leal F, De-Deus G, Brandão C, Luna AS, Fidel SR, Souza EM. Comparison of the root end seal provided by bioceramic repair cements and white MTA, *Int Endod J*. 2011 Jul;44(7):662-8.
25. Hirschberg CS, Patel NS, Patel LM, Kadouri DE, Hartwell GR. Comparison of sealing ability of MTA and EndoSequence Bioceramic Root Repair Material: a bacterial leakage study. *Quintessence Int*. 2013 May1;44(5):e157–62.
26. Lovato KF, Sedgley CM. Antibacterial activity of endosequence root repair material and proroot MTA against clinical isolates of *Enterococcus faecalis*. *J Endod*. 2011 Nov;37(11):1542-6.
27. Alanezi AZ, Jiang J, Safavi KE, Spangberg LS, Zhu Q. Cytotoxicity evaluation of endosequence root repair material. *Oral Surg Oral Med Oral Pathol Oral Radiol Endod*. 2010 Mar;109(3):e122-5.
28. Ciasca M, Aminoshariae A, Jin G, Montagnese T, Mickel A. A Comparison of the Cytotoxicity and Proinflammatory Cytokine Production of EndoSequence Root Repair Material and ProRoot Mineral Trioxide Aggregate in Human Osteoblast Cell Culture Using Reverse-Transcriptase Polymerase Chain Reaction. *J Endod*. 2012 Apr 1;38(4):486–9.
29. Damas BA, Wheeler MA, Bringas JS, Hoen MM. Cytotoxicity comparison of mineral trioxide aggregates and EndoSequence bioceramic root repair materials. *J Endod*. 2011 Mar;37(3):372-5.
30. Ma J, Shen Y, Stojicic S, Haapasalo M. Biocompatibility of two novel root repair materials. *J Endod*. 2011 Jun1;37(6):793–8.

31. Chen I. Calcium Silicate-based Bioceramics as a Root-end Filling Material: Clinical Efficacy and the Mechanism of Its Action. Master Thesis. University of Pennsylvania. 2013. Chapter 3: 40-53.
32. Kohli MR, Yamaguchi M, Setzer F, Karabucak B. Spectrophotometric Analysis Of Coronal Tooth Discoloration Induced By Various Bioceramic Cements and Other Endodontic Materials. Submitted for publication. J Endod.
33. Chen I, Karabucak B, Wang C, Wang HG, Koyama E, Kohli MR, Nah HD, Kim S. Healing after root-end microsurgery by using mineral trioxide aggregate and a new calcium silicate-based bioceramic material as root-end filling materials in dogs. J Endod. 2015 Mar;41(3):389-99.
34. Shinbori N, Grama AM, Patel Y, Woodmansey K, He J. Clinical outcome of endodontic microsurgery that uses EndoSequence BC root repair material as the root-end filling material. J Endod. 2015 May;41(5):607-12.
35. Bender IB, Seltzer S. Roentgenographic and direct observation of experimental lesions in bone: I. J Endod 2003;29:702-6.
36. Estrela C, Bueno MR, Leles CR, Azevedo B, Azevedo JR. Accuracy of cone beam computed tomography and panoramic radiography for the detection of apical periodontitis. J Endod 2008;34:273-9.
37. Paula-Silva FG, Wu MK, Leonardo MR, da Silva LA, Wesselink PR. Accuracy of periapical radiography and cone beam computed tomography scan in diagnosing apical periodontitis using histopathological findings as a gold standard. J Endod 2009;35:1009-12.
38. Low K, Dula K, Burgin W, von Arx T. Comparison of periapical radiography and limited cone beam computed tomography in posterior maxillary teeth referred for apical surgery. J Endod 2008;34:557-62.
39. Barone C, Dao TT, DMD, Basrani BB, Wang N, Friedman S. Treatment Outcome in Endodontics: The Toronto Study—Phases 3, 4, and 5: Apical Surgery. J Endod. 2010 Jan;36(1):28-35.
40. von Arx T, Penārrocha M, Jensen S. Prognostic Factors in Apical Surgery with Root-end Filling: A Meta-analysis. J Endod. 2010 Jun;36(6):957-73.

Research Aims

This is a prospective randomized clinical trial (RCT) in which subjects will undergo EMS procedure with one of two filling materials and then undergo follow-up evaluation 6 months, 1 and 2 years post surgery.

The research aims of the study are:

1. To evaluate the clinical outcome of EMS by comparing MTA with ERRM in a RCT with clinical, PA and CBCT evaluations after 6 months, 1 and 2 years post surgery.
2. To identify any possible prognostic factors that may have affected the healing outcome

The null hypothesis is:

a-There is not a statistically significant difference between the success rates of EMS using MTA as retro-filling material versus those utilizing ERRM.

b-There is not a statistically significant difference between any prognostic factor and EMS success rate.

Abstract

Introduction: The purpose of this study was to compare PA and CBCT healing after EMS using MTA or ERRM as root-end filling materials in a randomized clinical trial.

Materials and Methods: EMS was performed on patients with persistent or recurrent AP. The root-end filling material was randomly assigned. Regular follow-up visits were scheduled 6 months, 1 and 2 years. PA and CBCT were taken and the tooth was investigated clinically. **Results:** Regardless of the material, the overall PA

and CBCT success rates were 95.6% and 89.1% respectively with no statistical significant difference. Evaluating each material separately, MTA success rate was 95.5% and 89.3% as assessed by PA and CBCT respectively. ERRM success rate was 95.8% and 88.7% as assessed by PA and CBCT respectively. Fisher exact test showed no statistical significant difference between the 2 materials. Pre-operative prognostic factors such as microsurgical classification, presence of cortical, size of lesion and root canal filling quality had significant effect on outcome. Follow-up factors such as alignment and depth of filling material and root fractures also had significant effect on outcome. **Conclusion:** The null hypothesis is accepted: there is no statistical significant difference in EMS outcome using RRM or MTA as retro-filling material. However, certain factors were found to have a significant association with outcome.

Keywords: Root Repair Material, ERRM, bioceramics, MTA, root-end filling, Endodontic microsurgery, periapical radiograph, CBCT, prognostic factors

Introduction

Endodontic surgery is a dental procedure to treat apical periodontitis in cases where non-surgical retreatment (ReTx) or initial root canal therapy (RCTx) were not successful (1). This may include situations with persistent or refractory intracanal infection after iatrogenic changes to the original canal anatomy (2) or microorganism in proximity of the constriction (3) and the apical foramen (4). Other reasons may be found in extraradicular infection, such as bacterial plaque on the apical root surface (5) or bacteria within the lesion itself (6-9). In the past, various techniques were suggested to render a safer and more predictable procedure, and to facilitate its execution. (10). For many years, the state of the art was the traditional approach using surgical burs and amalgam for root end filling (11-13).

Modern techniques incorporate the use of US and more biocompatible filling materials such as IRM, SuperEBA and MTA (14). EMS is the most recent step in the evolution of periradicular surgery applying not only modern ultrasonic preparation and filling materials but also incorporating microsurgical instruments, and high power magnification (15). Weighted pooled success rates were established in meta-analyses with cumulative outcomes for traditional approaches of 59.0% (16), for contemporary techniques of 88.1% (17) and for EMS of 93.5% (16,17).

Ideally, a root-end filling material should be biocompatible, bactericidal, or at least bacteriostatic. It should be neutral to adjacent tissues and also provide excellent sealing. Moreover, it should promote the regeneration of the original tissues (18).

Contemporary root end filling materials in endodontics include IRM, SuperEBA, or MTA. IRM is a poly-methyl methacrylate (PMMA) reinforced zinc oxide eugenol cement. SuperEBA, a composition of zinc oxide and aluminum oxide mixed with o-ethoxybenzoic acid and eugenol (19-21). SuperEBA (Bosworth, Skokie, IL) cement as a root-end filling material was suggested by Oynick and Oynick (20). It was shown to be superior to amalgam in terms of sealing ability, apical tissue compatibility, and their regeneration potential (22,23). MTA has the same composition as Portland cement, but has added bismuth oxide for radiopacity and is highly purified. As a root-end filling material, MTA was introduced to endodontics by Torabinejad et al in 1993 (24). It contains tricalcium silicate, dicalcium silicate, bismuth oxide, and small proportions of tricalcium aluminate and calcium sulfate (25). Although no statistically significant difference was found in regard to the clinical outcome of root-end surgery between the use of IRM, SuperEBA and MTA, there is evidence supporting the fact that MTA has a better histologic biocompatibility than IRM, SuperEBA, or the traditionally used amalgam. It was shown to be less cytotoxic than amalgam, IRM, or SuperEBA (26,27) and had an antimicrobial effect (28). Moreover, MTA was shown to have excellent sealing ability (26,29-31) and promoted osteoblast activity (32,33). Results of MTA studies in dogs and monkeys showed that MTA caused significantly less inflammation than amalgam. Cementum bridges formed directly over MTA root-end fillings, confirming tissue compatibility and the potential for cementogenesis (18,34,35). In a dog experiment, the regenerated bone over root end fillings with MTA established the same distance to the filling as the average thickness of a healthy periodontal

ligament in dogs (36). Despite the biological advantages, due to the composition of the material, MTA exhibits difficult handling characteristics (37,38), including granular consistency (38), slow setting time (38-40), and initial looseness (38).

Recently, a new type of material was introduced to clinical dentistry. Products labeled as "bioceramics", available as sealers or root-end filling, respectively root-repair materials promise shorter setting times and a better consistency for clinical handling. ERRM is a bioceramic material that is available as a pre-mixed moldable putty or as preloaded syringeable paste (consisting of calcium silicates, zirconium oxide, tantalum oxide, calcium phosphate monobasic). It is hydrophilic and has a working time of approximately 30 minutes and setting time of 2-4 hours (40,41). Cytotoxicity studies found ERRM to be similar to MTA (42-44). iRootSP (Innovative BioCeramix Inc, Vancouver, Canada), the name of the bioceramic material distributed in Canada, has been demonstrated to possess adequate apical sealing ability (45), mild cytotoxicity (46), and antibacterial activity for up to 7 days after placement (47).

Many of the studies available on contemporary root-end surgery or EMS are only of average or better quality, but rarely of best quality (16,17) and none address CBCT methods for evaluating success. Similarly, Mead et al. (52) investigated the quality of clinical investigations on the outcome of endodontic surgery and found no level of evidence-1 randomized clinical trials, only two level of evidence-2 randomized clinical trials comparing the outcomes of surgical treatment with that of nonsurgical retreatment. The remainder being level of evidence-3 case control studies and a

majority of level of evidence-4 low quality cohort or case series investigations (52). A large-scale prospective randomized clinical trial would not only answer these questions, but also contribute in the form of a high ranked evidence-based investigation for statistical validity. The purpose of the present study was to evaluate outcome of EMS when using ERRM or MTA as a root-end filling material in RCT and to investigate for outcome predictors.

Materials & methods

The protocol of the present study was reviewed and approved by the Institutional Review Board (IRB) of University of Pennsylvania (IRB number: 815114). Patients from the School of Dental Medicine (SDM) at University of Pennsylvania were seen for clinical treatment in the Endodontic Clinic. The Endodontic Clinic almost exclusively handles all endodontic procedures carried out at the SDM, with the exception of Penn Dental Faculty Practice facilities. All patients are referred from the Restorative Department of the SDM, emergency admissions or are referred from a private practice and come by appointment directly to the clinic.

Case Selection

Patients presenting to the Department of Endodontics at SDM for routinely treatment planned root-end surgery of teeth with persistent or recurrent apical periodontitis with a history of unsuccessful primary or secondary root canal therapy were asked to take part in the study. Patients were eligible to participate in the study if the following inclusion criteria were met: 1. Patient volunteering to

participate in the study. 2. Patients are 18 years or above. 3. Non-contributory medical history (Patient can be seen for regular dental appointment in SDM; ASA classes I and II). 4. Radiographic or clinical presence of apical periodontitis. 5. Patient is scheduled and has consented to a root-end surgery procedure as part of his/her regular treatment plan. 7. History of previous endodontic treatment on the tooth. 8. Tooth to be treated is microsurgical classification A, B or C (true endodontic lesions). 9. Lesion size less than 10 mm in diameter. Patients were not eligible to participate in the study if any of the following exclusion criteria applies:

1. Patient does not volunteer.
2. Patient is below 18 years old.
3. Contributory medical history (Patient can not be seen for regular dental appointment in SDM; ASA classes III-V).
4. No radiographic or clinical presence of apical periodontitis.
5. Teeth with insufficient coronal restoration or no treatment plan to receive proper permanent coronal restoration shortly after the surgical procedure.
7. No history of previous endodontic treatment.
8. Teeth affected by dental trauma or cavities that may compromise restorability.
9. Tooth to be treated is microsurgical classification D, E or F (combined endodontic and periodontal lesions).
10. Mobility greater than I.
11. Radiographic presence of resorptive processes.
12. History of previous surgery (resurgery).
13. Evidence of a preexisting vertical root fracture, which was seen radiographically as a J-shaped radiolucency.
14. Presence of a lesion equal or greater than 10 mm in diameter.

Surgical Procedure and Material Randomization

All EMS procedures in SDM endodontic were performed by post-graduate residents and followed the same guidelines and principles for root-end surgery as outlined by Kim and Kratchman (15). With the exception of the randomized root-end filling material, all procedures will follow the exact standard protocol.

Before treatment, patients were thoroughly informed about the nature, potential risks and alternatives of EMS. Patients were presented with the regular consent forms for EMS, including the acknowledgement of privacy practices and a patient understanding and informed consent form within SDM.

After verification of eligibility and informed consent as outlined above, PA of the tooth to be treated (Carestream, CS 2100, Atlanta, GA) as well as a CBCT (when available) of the area were taken to verify lesion size, root anatomy and to identify proximal structures such as the sinus cavity, the mental or infra-alveolar nerves, or adjacent roots. Three CBCT machines were employed depending on the time EMS and follow-up were done:

1-From 2011 to 2013: Suni Medical Imaging (San Jose, CA); SUNI3D,FOV 5x5cm, voxel size 0.08mm.

2- From 2013 to 2014: Carestream (Atlanta, GA); CS 9000 3D, FOV 7.5x3.7cm, voxel size 0.076mm.

3- From 2014 to 2015: Morita (Irvine, CA); Veraviewepocs 3D R100, FOV 4x4cm , voxel size 0.125mm.

Patients were then scheduled for EMS.

On the day of the surgery the patient's medical history was reviewed and, if necessary, updated. Patients were locally anesthetized with 2% Lidocaine 1:100k epinephrine and 2% Lidocaine 1:50k epinephrine (Septodont, Brampton, ON, Canada) for surgical hemostasis. After verification of probing depths, a submarginal or intra-sulcular full-thickness flap was raised for access to the inflammatory process surrounding the root tip(s). Using a surgical operating microscope (Opmi PROergo; Carl Zeiss, Gottingen, Germany), the lesion site was localized and inflammatory tissue removed by a surgical curette. The apical portion of the root tip(s) was resected with a Lindemann bur (Henry Schein Inc., Melville, NY, USA) in an Impact Air 45 handpiece (NSK; Nakanishi Inc, Kanuma-shi Tochigi-ken, Japan) to remove areas with apical ramifications that are a common harbor for residual intra-canal infection. Under high magnification, the resected root surface was inspected after staining with methylene blue (Sigma-Aldrich, St Louis, MO) to identify possible fractures, missed canals, isthmuses or unresected areas. If at this stage of the surgery a tooth was deemed unrestorable or irreversibly damaged, the tooth was extracted and the surgical flap repositioned, sutured and the patient referred to the appropriate department. In this case, the patient would not participate in the investigation. If not, then the root end preparation was carried out with Jetip US (B&L Bio, Bala Cynwud, PA) under high magnification. At this point, the operator would use a database for randomization through the University of Pennsylvania web servers to assign teeth to the MTA group or the ERRM group. The patient was blinded to the type of material used. The two materials differ in color and

consistency. The operator always knew which material was used and couldn't be blinded. However, the materials cannot be distinguished radiographically.

After root-end filling, the surgical site was cleaned, the flap repositioned and sutured. PA were taken to verify the procedure. Patients received postoperative instructions and were scheduled for a surgical follow-up after 3-5 days for suture removal.

Clinical and Radiographic Evaluation

A manifest of all EMS with randomized retro-filling material was handed to the Masters candidate (C.S.) who scheduled follow-up visits via telephone. Patients were called in a sequential manner starting with the earliest dates. Each follow-up visit included a routine clinical examination as well as PA and a limited volume CBCT. The Masters candidate completed the clinical examination whereas radiographic evaluation (PA & CBCT) was completed by a special jury. A surgical evaluation form was created specially to be used for outcome evaluation and to identify any prognostic factor (Table 1). The pre-operative clinical data was assessed by the Masters candidate and included:

- 1- Patient sex: specified in his/her chart
- 2- Presence of signs and/or symptoms: specified in clinical notes
- 3- Initial pulpal diagnosis at time of root canal treatment: specified clinical notes.

This information could not be obtained for patient referred from a private practice.

4- Apical diagnosis: specified in clinical notes

5- Treatment rendered prior to surgery (primary or secondary root canal therapy): specified in clinical notes. This information was also non obtainable for patients referred from a private practice.

6- Tooth position (Anterior vs posterior, maxilla vs mandible)

7- Microsurgical classification: as seen on PA (15). Class A represents the absence of a periapical lesion, no mobility and normal pocket depth, but unresolved symptoms after non- surgical approaches have been exhausted. Clinical symptoms are the only reason for the surgery. Class B represents the presence of a small periapical lesion together with clinical symptoms. The tooth has normal periodontal probing depth and no mobility. The teeth in this class are ideal candidates for microsurgery. Class C teeth have a large periapical lesion progressing coronally but without periodontal pocket and mobility .

8- Presence of broken instrument in the affected root(s): as seen on CBCT

9- Root canal filling quality: as seen on PA (53). A root canal filling was adequate when it exhibited a homogeneous radiopaque material with no visible voids or space between the material and the walls of the canal or within the body of the material itself. Root canal fillings that did not show a uniform radiodensity and/or with canals space visible laterally and apically were inadequate.

10- Root canal filling length (54): as seen on PA. A root canal filling ending 0-2mm from the radiographic apex was adequate. Any root canal filling not within that range was inadequate.

11- Presence of cortical plate: as seen on CBCT.

12- Lesion diameter: as measured on CBCT. The diameter in millimeters was measured in all 3 dimensions and the largest one was recorded.

The following follow-up clinical data were also assessed by CS:

1- Presence of signs and/or symptoms

2- Type of retro-filling material that was randomly assigned

3- Alignment of the retro-filling material: as seen on CBCT

4- Depth of the retro-filling material: as measured on CBCT

5- Detection of root fracture intra-operatively: as seen in clinical notes

6- Presence of missed canals that were addressed surgically: as seen on CBCT

7- If the tooth serves as a bridge abutment

8- Presence of interproximal contacts

9- Grafting of the surgical site prior to suturing: specified in clinical notes

10- Type of coronal restoration

The scoring criteria used for potential prognostic factors can be found in tables 2a and 2b.

The Master's candidate however did not perform follow-up PA and CBCT interpretation.

Three calibrated examiners reviewed all the radiographic images (BK, SK, and MK).

They are experienced endodontists familiar with EMS. The examiners were blinded to the material used and to time of follow-up. A specific score was assigned for each case when all three examiners agreed or achieved a consensus after discussion. Pre-operative, post-operative, and follow-up PA were projected on a big screen in a dark room and were displayed in a random fashion. Healing on PA was determined as complete, incomplete, uncertain, unsatisfactory, according to the criteria established by Rud et al (55) and Molven et al (56) (Table 3, Figure 1). Complete and incomplete healing were combined as success. Uncertain and unsatisfactory healing were combined as failure.

Pre-operative CBCT (when available) and follow-up CBCT were also projected in a dark room and viewed using OsriX (Pixmeo, Geneva, Switzerland) in multi-planar reconstruction mode (MPR). Axes were aligned to obtain ideal mesio-distal and bucco-lingual sections: the sagittal plane was parallel to M-D long axis of the tooth; the coronal plane was aligned along with the root canal, and both planes passed through the middle of the resected root-end surface. The slice thickness was set to 0.125mm. After proper alignment, healing was evaluated using the "Penn 3D criteria" (Table 4, figure 2). Complete and limited healing were combined as success.

Statistical Analysis

All data were first analyzed descriptively. Significant associations between the outcome and all the variables were examined by using the Fisher exact test to identify potential prognostic factors. All statistical tests were performed as two-tailed with the level of significance set at $P < 0.05$. All statistical analyses were performed using the R software package v3.1.0 (<http://www.r-project.org>).

Results

The randomization process debuted in July 2011 and is still ongoing. The last recalled patient included in this study dates back to November 2014. From July 2011 to November 2014, a total of 243 patients were enrolled in the study. 17 patients were lost due to extractions as indicated in their clinical notes and/or via telephone communication when recalled for follow-up. Of the remaining 226 patients, 101 patients were recalled corresponding to a recall rate of 44.5%. Follow-up time ranged from 6 to 24 months and over, with a mean of 15 months. The 101 patients totalized 143 roots: 68 roots in MTA group and 75 roots in ERRM group. Each root was then considered as one case. The follow-up periods were further divided into 3 time points: Group 1: 0-11 month totalizing 36 cases (16 MTA and 20 ERRM), group 2: 12-23 month totalizing 57 cases (34 MTA and 23 ERRM), and group 3: 24 month and over totalizing 50 cases (18 MTA and 32 ERRM).

During CBCT evaluation it was noticed that 6 cases had procedural errors as follows: 1 MTA case in group 1, 1 MTA case in group 2, and 2 ERRM cases in group 3 had their retro-filling material misaligned with the main root axis and even outside the root canal walls (Figure 3a). 1 MTA case in group 2 and 1 ERRM case in group 3 had a missing canal pre-operatively that was neither retro prepared nor retro-filled during EMS (Figure 3b). Thus, our clinical and radiographic evaluation were dichotomized into two group: Group A containing procedural errors, and group B excluding procedural errors.

Periapical Radiograph Evaluation (Figure 4a)

Group A: The overall success rate of EMS (all time points and retro-filling material combined) was 93.7% according to PA. When looking at each time point separately but combining retro-filling material, the success rate was 97.2% at 0-11 months, 94.7% at 12-23 months, and 90% at 24 months and over.

When evaluating the outcome according to PA as a function of retro-filling, MTA group showed 95.6% success when combining all time points. This translated into 93.8% success at 0-11 months , 94.1% success at 12-23 months, and 100% at 24 months and over.

ERRM group showed 92% success when combining all time points. This translated into 100% success at 0-11 months , 95.7% success rate 12-23 months, and 84.4% success at 24 months and over.

Group B: The overall success rate of EMS (all time points and retro-filling material combined) was 95.6% according to PA. When looking at each time point separately but combining retro-filling material, the success rate was 97.1% at 0-11 months, 94.5% at 12-23 months, and 95.7% at 24 months and over.

When evaluating the outcome according to PA as a function of retro-filling, MTA group showed 95.5% success when combining all time points. This translated into 93.3% success at 0-11 months , 93.9% success at 12-23 months, and 100% success at 24 months and over.

ERRM group showed 95.8% success when combining all time points. This translated into 100% success at 0-11 months , 95.5% success at 12-23 months, and 93.1% success at 24 months and over.

Cone-Beam Computed Tomography Evaluation (figure 4b)

Group A: The overall success rate of EMS (all time points and retro-filling material combined) was 86.7% according to CBCT. When looking at each time point separately but combining retro-filling material, the success rate was 88.9% at 0-11 months, 89.5% at 12-23 months, and 82% at 24 months.

When evaluating the outcome according to CBCT as a function of retro-filling, MTA group showed 89.7% success when combining all time points. This translated into 87.5% success at 0-11 months , 91.2% success at 12-23 months, and 88.9% success at 24 months and over.

ERRM group showed 84% success when combining all time points. This translated into 90% success at 0-11 months , 87% success at 12-23 months, and 78.1% success at 24 months and over.

Group B: The overall success rate of EMS (all time points and retro-filling material combined) was 89.1% according to CBCT. When looking at each time point separately but combining retro-filling material, the success rate was 88.6% at 0-11 months, 90.1% at 12-23 months, and 87.2% at 24 months and over.

When evaluating the outcome according to CBCT as a function of retro-filling, MTA

group showed 89.3% success when combining all time points. This translated into 86.7% success at 0-11 months, 90.9% success at 12-23 months, and 88.9% success at 24 months and over.

ERRM group showed 88.7% success when combining all time points. This translated into 90% success at 0-11 months, 90.9% success at 12-23 months, and 86.2% success at 24 months.

Periapical Radiograph VS Cone-Beam Computed Tomography

Out of 143 cases in group A, 10 patients had discordant results where PA and CBCT received different scores. In all these cases, PA result showed a success whereas CBCT showed a failure.

Out of 137 cases in group B, 9 patients had discordant results between PA and CBCT. In all these cases, PA result showed a success whereas CBCT showed a failure.

In general, achieving a success on CBCT was more difficult (stringent) than on PA. However there was no significant difference between success and failure as measured by PA or CBCT between MTA or ERRM when looking at all time points or each time point individually.

Periapical Radiographic Assessment of Prognostic Factors

Group A:

3 pre-operative factors had significant influence on outcome

1- Microsurgical Classification

Superior healing was associated with microsurgical classification A & B. Overall (combining material groups and all time points), Fisher exact test revealed significant association ($p=0.019$) between microsurgical classification and PA outcome. EMS had 6.2 times the odds of unsatisfactory result when microsurgical classification was C (odds ratio= 6.2, 95% CI, 1.231–31.346). No further association was found between material groups and time point groups.

2- Presence of Cortical Buccal Plate

Superior healing was associated with presence of cortical buccal plate. At 24 months and over, and combining material groups, Fisher exact test revealed significant association ($p=0.015$) between presence of cortical buccal plate and PA outcome. None of the treated roots showed unsatisfactory PA healing at 24 months and over when cortical buccal plate was present. No further association was found between material groups and time point groups.

3- Lesion Diameter

Superior healing was associated with a diameter less than 5mm. Overall (combining material groups and all time points), Fisher exact test revealed significant association ($p=0.026$) between lesion diameter and PA outcome. EMS had 6.5 times the odds of unsatisfactory result when the lesion was 5mm or more (odds ratio= 6.5, 95% CI, 1.203–35.674). No further association was found between material groups and time point groups.

2 follow-up factors had significant influence on outcome

1- Alignment of retro-filling material

Superior healing was associated with adequate alignment. Overall (combining material groups and all time points), Fisher exact test revealed significant association ($p=0.01$) between alignment of retro-filling material and PA outcome. . EMS had 38 times the odds of unsatisfactory result when alignment was inadequate (odds ratio= 38, 95% CI, 3.064–471.299).

At 24 months and over and looking at both material groups, Fisher exact test revealed significant association ($p=0.008$) between alignment of retro-filling material and PA outcome. All of the treated roots showed unsatisfactory PA healing at 24 months and over when alignment was inadequate.

A significant association ($p=0.005$) was found between alignment of ERRM and PA result when all time points were combined. All of the ERRM treated roots showed unsatisfactory PA healing when alignment was inadequate. Further, this association was significant ($p=0.02$) between alignment of ERRM and PA outcome at 24 months and over. All of the ERRM treated roots showed unsatisfactory PA healing at 24 months and over when alignment was inadequate.

2- Depth of retro-filling material

Superior healing was associated with adequate depth. Overall (combining material groups and all time points), Fisher exact test revealed significant association ($p=2.938e-07$) between depth of retro-filling material and PA outcome. EMS had 81 times the odds of unsatisfactory result when depth was inadequate (odds ratio= 81, 95% CI, 9.363–706.502).

At 12-23 month and looking at both material groups, Fisher exact test revealed significant association ($p=0.004$) between alignment of retro-filling material and PA outcome. None of the treated roots showed unsatisfactory PA healing at 12-23 months when depth was adequate. The same association was found at 24 months and over ($p=0.001$), (odds ratio= 41, 95% CI, 3.646–461.031).

A significant association ($p=0.005$) was found between depth of MTA and PA result when all time points were combined. None of the MTA treated roots showed unsatisfactory PA healing when depth was adequate. Further, this association was significant ($p=0.026$) at 12-23 months. None of the MTA treated roots showed unsatisfactory PA healing at 12-23 months when depth was adequate.

A significant association ($p=0.0002$) was found between depth of ERRM and PA result when all time points were combined. EMS had 44 times the odds of unsatisfactory result when ERRM depth was inadequate (odds ratio= 44, 95% CI, 4.508–435.067). Further, this association was significant ($p=0.004$) at 24 months and over. EMS had 32 times the odds of unsatisfactory result at 24 months and over when ERRM depth was inadequate (odds ratio= 32, 95% CI, 2.631–389.245).

Group B:

1 pre-operative factor had significant influence on outcome

1- Microsurgical Classification

Superior healing was associated with microsurgical classification A & B. Overall (combining material groups and all time points), Fisher exact test revealed significant association ($p=0.0256$) between microsurgical classification and PA

outcome. EMS had 9 times the odds of unsatisfactory result when microsurgical classification was C (odds ratio= 9, 95% CI, 1.40–57.60). No further association was found between material groups and time point groups.

1 follow-up factor had significant influence on outcome

1- Depth of retro-filling material

Superior healing was associated with adequate depth. Overall (combining material groups and all time points), Fisher exact test revealed significant association ($p=9.186e-05$) between depth of retro-filling material and PA outcome. EMS had 50 times the odds of unsatisfactory result when depth was inadequate (odds ratio= 50, 95% CI, 9.363-706.502).

At 12-23 month and looking at both material groups, Fisher exact test revealed significant association ($p=0.005$) between alignment of retro-filling material and PA outcome. None of the treated roots showed unsatisfactory PA healing at 12-23 month when the depth of the retro-filling material was adequate.

A significant association ($p=0.001$) was found between depth of MTA and PA result when all time points were combined. None of the MTA treated roots showed unsatisfactory PA healing when the depth of the retro-filling material was adequate. Further, this association was significant ($p=0.028$) at 12-23 months. None of the MTA treated roots showed unsatisfactory PA healing at 12-23 months when the depth of the retro-filling material was adequate.

A significant association ($p=0.04$) was found between depth of ERRM and PA result when all time points were combined. EMS had 17 times the odds of unsatisfactory result when ERRM depth was inadequate (odds ratio= 17, 95% CI, 1.396-217.626).

Cone-Beam Computed Tomography Assessment of Prognostic Factors

Group A:

2 pre-operative factors had significant influence on outcome

1- Microsurgical Classification

Superior healing was associated with microsurgical classification A & B. Overall (combining material groups and all time points), Fisher exact test revealed significant association ($p=0.018$) between microsurgical classification and CBCT outcome. EMS had 2.5 times the odds of unsatisfactory result when microsurgical classification was C (odds ratio= 2.5, 95% CI, 0.916-6.732).

2- Root Canal Filling Quality

Superior healing was associated with adequate root canal filling quality. At 24 months and over, and combining material groups, Fisher exact test revealed significant association ($p=0.0263$) between quality of root canal filling and CBCT outcome. EMS had 7.4 times the odds of unsatisfactory result when root canal filling was inadequate (odds ratio= 7.4, 95% CI, 1.391-39.356).

Further, this association was significant ($p=0.047$) with ERRM at 24 month and over. EMS had 7 times the odds of unsatisfactory result when ERRM was used on inadequate root canal fillings (odds ratio= 7, 95% CI, 1.112-44.058).

3 follow-up factors had significant influence on outcome

1- Alignment of retro-filling material

Superior healing was associated with adequate alignment. Overall (combining material groups and all time points), Fisher exact test revealed significant association ($p=0.046$) between alignment of retro-filling material and CBCT outcome. EMS had 14 times the odds of unsatisfactory result with inadequate alignment (odds ratio= 14, 95% CI, 1.244–168.269).

At 24 months and over and looking at both material groups, Fisher exact test revealed significant association ($p=0.029$) between alignment of retro-filling material and CBCT outcome. None of the treated roots showed unsatisfactory CBCT healing at 24 months and over when alignment was adequate. A significant association ($p=0.024$) was found between alignment of ERRM and CBCT result when all time points were combined. None of the ERRM treated roots showed unsatisfactory CBCT healing when alignment was adequate. Further, A significant association ($p=0.042$) was found between alignment of ERRM and CBCT result at 24 months and over. None of the ERRM treated roots showed satisfactory CBCT healing at 24 months and over when alignment was inadequate.

2- Depth of retro-filling material

Superior healing was associated with adequate depth. Overall (combining material groups and all time points), Fisher exact test revealed significant association ($p=8.66e-07$) between depth of retro-filling material and CBCT outcome. EMS had 18 times the odds of unsatisfactory result with inadequate depth (odds ratio= 18,

95% CI, 5.644–54.696).

At time point 12-23 month and looking at both material groups, Fisher exact test revealed significant association ($p=0.0003$) between alignment of retro-filling material and CBCT outcome. EMS had 46 times the odds of unsatisfactory result with inadequate depth (odds ratio= 46, 95% CI, 4.444–476.105). The same association was found at 24 months and over ($p=0.003$), (odds ratio= 16; 95% CI, 2.714–92.361).

A significant association ($p=0.002$) was found between depth of MTA and CBCT result when all time points were combined. EMS had 19 times the odds of unsatisfactory result with inadequate MTA depth (odds ratio= 19, 95% CI, 3.116–115.1858). Further, this association was significant ($p=0.003$) at 12-23 months. None of the MTA treated roots showed CBCT unsatisfactory healing at 12-23 months when depth was adequate.

A significant association ($p=0.0002$) was found between depth of ERRM and CBCT result when all time points were combined. EMS had 16 times the odds of unsatisfactory result with inadequate ERRM depth (odds ratio= 16, 95% CI, 3.746–70.408). Further, this association was significant ($p=0.002$) at 24 months and over. EMS had 29 times the odds of unsatisfactory result at 24 months and over with inadequate ERRM depth (odds ratio= 29, 95% CI, 3.232–255.755).

3- Detection of Root Fracture

Superior healing was associated with absence of root fracture. Overall (combining material groups and all time points), Fisher exact test revealed significant

association ($p=0.046$) between presence of root fracture and CBCT outcome. EMS had 14 times the odds of unsatisfactory result when root fracture was detected (odds ratio= 14, 95% CI, 1.244–168.269). Further, a significant association ($p=0.026$) was found between MTA fractured cases and CBCT when all time points were combined. EMS had 24 times the odds of unsatisfactory result when root fracture was detected on MTA treated roots (odds ratio= 24, 95% CI, 1.841–312.946).

Group B:

1 pre-operative factor had significant influence on outcome

1- Root Canal Filling Quality

Superior healing was associated with adequate root canal filling quality. At 24 months and over, and combining material groups, Fisher exact test revealed significant association ($p=0.035$) between quality of root canal filling and CBCT outcome. EMS had 9 times the odds of unsatisfactory result root canal filling was inadequate (odds ratio= 9, 95% CI, 1.378–62.091).

When looking at each material group separately, there was a significant association ($p=0.028$) between quality of root canal filling and CBCT outcome for ERRM group. EMS had 6 times the odds of unsatisfactory result when ERRM was used on inadequate root canal filling (odds ratio= 6, 95% CI, 1.238–27.475). Further, this association was significant ($p=0.033$) with ERRM at 24 month and over. EMS had 16 times the odds of unsatisfactory result at 24 months and over when ERRM was used on inadequate root canal filling (odds ratio= 16, 95% CI, 1.289–192.460).

2 follow-up factors had significant influence on outcome

1- Depth of retro-filling material

Superior healing was associated with adequate depth. Overall (combining material groups and all time points), Fisher exact test revealed significant association ($p=3.964e-05$) between depth of retro-filling material and CBCT outcome. EMS had 14 times the odds of unsatisfactory result when depth was inadequate (odds ratio= 14, 95% CI, 4.234–48.631).

At time point 12-23 month and looking at both material groups, Fisher exact test revealed significant association ($p=7.244e-05$) between alignment of retro-filling material and CBCT outcome. None of the treated roots showed unsatisfactory healing on CBCT at 12-13 months when depth was adequate.

A significant association ($p=0.002$) was found between depth of MTA and CBCT result when all time points were combined. EMS had 18 times the odds of unsatisfactory result when MTA depth was inadequate (odds ratio= 18, 95% CI, 3.005–111.869). Further, this association was significant ($p=0.004$) at 12-23 months. None of the MTA treated roots showed unsatisfactory CBCT healing at 12-23 months when depth was adequate.

A significant association ($p=0.007$) was found between depth of ERRM and CBCT result when all time points were combined. EMS had 12 times the odds of unsatisfactory result when MTA depth was inadequate (odds ratio= 12, 95% CI, 2.206–61.002). Further, this association was significant ($p=0.026$) at 12-23 months. None of the ERRM treated roots showed unsatisfactory CBCT healing at 12-23

months when depth was adequate.

2- Detection of Root Fracture

Superior healing was associated with absence of root fracture. Overall (combining material groups and all time points), Fisher exact test revealed significant association ($p=0.03$) between presence of root fracture and CBCT outcome. EMS had 19 times the odds of unsatisfactory result when root fracture was detected (odds ratio= 19, 95% CI, 1.578–219.569). Further, a significant association ($p=0.026$) was found between MTA fractured cases and CBCT when all time points were combined. EMS had 23 times the odds of unsatisfactory result when root fracture was detected on MTA treated roots (odds ratio= 23, 95% CI, 1.778–302.645).

Discussion

Key findings

This study showed that EMS is a predictable procedure with high success rate regardless if MTA or ERRM was used as a retro-filling material. This study also showed that using MTA or ERRM did not significantly differ in terms of PA or CBCT healing. Microsurgical classification, presence of cortical buccal plate, lesion size, root canal filling quality, alignment and depth of retro-filling material, and detection of root fracture showed significant association with outcome. Based on these results, we failed to reject the second part (part b) of our null hypothesis.

Strengths and Limitations of the Study

There are several strengths and limitations that need to be addressed. First, ERRM has a white color, and MTA has a grey color meaning that the operator could not be

blinded to the material that was chosen via the randomization process. This might be a significant source of performance bias. A performance bias may complicate efforts to establish a cause-effect relationship between procedures and outcome. Second, even if EMS is a strictly standardized procedure in the Endodontics clinic, technical variations by operator commonly occur in flow of operation, and technical maneuvers. The operator's experience may have a significant effect on the outcome thereof contributing to performance bias.

On the other hand, the strength of the present study is that randomization with regard to root-end filling materials was performed, and the examiners were blinded as to type of retro-filling used and time of follow-up. The randomization procedure ensures that groups have an even distribution of known and unknown confounding factors. Moreover, blinding the examiners prevents them from preferring one material to another.

Interpretation and implications

EMS is the treatment performed on the root apices of an infected tooth, followed by placement of a retro-filling material to seal the root end. In the past, this surgical procedure was performed by endodontists, oral surgeons and general practitioners using the then-traditional techniques of preparing the canal space with a round bur attached to a straight handpiece and using amalgam as the root-end filling material. Advances over the past decades, supported by ongoing research, have led to a refinement of these techniques, materials and instruments. These advancements are centered on the use of the surgical operating microscope

to provide unsurpassed magnification and illumination for all phases of the treatment process and on the use of new promising retrofilling material. As a result, the procedures have changed in ways that significantly affect the success, the overall case selection, the application for this now-predictable procedure, as well as the postoperative healing sequelae (15).

Among the many widely used filling materials, MTA and ERRM have been shown to be superior material for EMS due to their excellent biocompatibility, osteo- and cemento-inductive capabilities, and effective antibacterial and sealing properties (18,36,42,44). The 2 materials are bioactive calcium cements classified in a broader group as BC. Hence, they should have similar clinical efficacy.

PA is the most common method to assess outcome of EMS. Rud et al (55) and Molven et al (56) developed criteria to do so based on correlation between histological findings and radiographic findings. Using Rud and Molven's criteria for success and failure, our results showed no significant difference between MTA and ERRM in terms of healing when evaluated using PA. Chen et al found the same results in their study (57). This can be due to either the fact that results are really not different, either due to lack of PA sensitivity in detecting differences between the 2 materials. In fact, many studies showed that PA is not a sensitive tool to detect AP. Thus, minute differences like PDL reformation and bone quality cannot be always detected on PA.

Since Endodontics relies on detecting disruptions in the periodontal ligament space measuring approximately 200µm, a more powerful tool was needed in order to

investigate EMS outcome. Hence we decided to use CBCT. CBCT has proven to be indispensable in Endodontics due to its superior sensitivity in detecting AP and its ability to give a three-dimensional view of the periapical area in question. Therefore, we assessed EMS outcome using CBCT. To our knowledge, there are no CBCT criteria approved of in the literature. Hence, "Penn 3D Criteria" for assessing EMS outcome on CBCT were developed in our department. The "Penn 3D Criteria" were inspired by the results obtained by Chen et al (57). In their study, Chen et al developed a special scoring system in which healing in different areas in sagittal and coronal views was evaluated. Their results showed superior healing when ERRM was used compared to MTA. Our results however showed no significant difference between MTA and ERRM in terms of healing when evaluated using CBCT. This can be due to either the fact that results are really not different, either due to the new criteria, which might be very strict and/or incomplete.

In term of prognostic factors, pre-operative factors such as patient gender, pulpal status, periapical status, tooth position, and presence of broken instrument did not significantly affect healing rates. Follow-up factors such as presence of missed canal, if the tooth in question serves as bridge abutment, interproximal contacts, grafting and type of coronal restoration did not significantly affect healing rates. To our knowledge, there is no study investigating the effect of broken instruments, missed canals, bridge abutments, and interproximal contacts on apical healing. It is reasonable to hypothesize that none had negative effect on sealing ability of either material and thus did not affect outcome.

Looking at group A, pre-operative factors such as microsurgical classification,

presence of cortical and a lesion diameter of 5mm or less significantly affected PA outcome. Similarly, CBCT showed microsurgical classification and root canal filling quality significantly affected PA outcome. When comparing these findings to group B, only microsurgical classification and root canal filling quality were found to be significant prognostic factors.

In terms of microsurgical classification and lesion diameter, one can speculate that the healing time for a large lesion (bigger than 5mm and/or involving a large periapical area) is longer and that it may show scar tissue healing, making radiographic healing determination more difficult. The presence of cortical buccal plate was only a significant prognostic factor at 24 month and over. At this time point all cases (21 total) that had a pre-operative cortical plate showed healing on PA regardless of material group. This could be explained by the fact that intentional osseous wound created when cortical is present to access periradicular tissues might activate bone formation, which would not be the case when access is already present due to the absence of cortical.

Another significant prognostic factor at 24 months and over was root canal filling quality when ERRM was used. This suggests that inadequate root canal fillings can function as a microbial reservoir and compromise the sealing effect of ERRM. Thus one would think to perform a ReTx before employing ERRM on poorly filled root canals. However, within our study, performing a ReTx did not affect outcome significantly. But looking at individual cases, 6 ERRM cases at 24 month and over were retreated before EMS. 2 of these cases were in group A and showed negative outcome on PA and CBCT. However 4 out of the remaining 4 cases showed positive

outcome on PA and CBCT suggesting that having a larger sample size could have yielded a significant association between ReTx and ERRM outcome at 24 months and over.

Looking at group A, follow-up factors such as alignment and depth of retro-filling material significantly affected PA outcome. Similarly, CBCT showed that in addition to alignment and depth, root fractures also significantly affected outcome. When comparing these findings to group B, only depth of retro-filling material significantly affected PA outcome. On CBCT, depth and root fractures were found to be significant prognostic factors.

Since group A included procedural errors such as alignment, it is not surprising that this is not a significant prognostic factor in group B which excludes procedural errors. In fact 4 out of 6 procedural errors had inadequately aligned retro-filling material. 2 of these cases received MTA and had a positive PA and CBCT outcome and 2 received ERRM but had a negative PA and CBCT outcome. The misaligned ERRM failed cases had also an inadequate depth. All of the misaligned MTA cases had adequate depth. This suggests that even when misaligned, sealing could be effective given that the retro-filling material is placed at a correct depth.

At 12-23 month, MTA depth was shown to be a significant prognostic factor in groups A and B as seen via PA and CBCT. ERRM depth on the other hand was shown to be a significant prognostic factor at 24 months and over for group A (PA and CBCT) and at 12-23 months for group B (PA and CBCT). Since depth of retro-filling material correlates with a proper seal, long-term seal of short filled MTA and ERRM cases can be compromised as soon as 1 year following apical surgery.

The presence of a root fracture during surgery, even if included in the root resection, was a significant prognostic factor as seen via CBCT in groups A and B. All of the fractured cases were in the MTA group, which is a coincidence, and all had negative outcome. This finding suggests that cases with root fractures have a poor prognosis and should be thoroughly assessed for extent of fracture during EMS.

CBCT Limitations (Figure 2G)

A common healing pattern observed on CBCT was seen in 3 different cases. It was so unique that it led us to attribute new healing criteria. These cases were attributed limited healing; complete healing can be observed in immediate vicinity of the resected root surface, but the site demonstrates an incomplete trabecular bone repair as illustrated by a volume of low density area despite complete cortical plate repair. To our knowledge, this healing pattern has never been reported in the literature. Our hypothesis is that the radiolucent area represents either scar tissue, either immature bone or bone-like tissue, all of which cannot be detected on CBCT. Further investigations with histologic correlation are necessary in order to identify the type of tissue present.

Generalizability

Despite the limited sample size in our study, the external validity was considered robust because patients were not highly selected. Only selection criteria inherent to undergoing a surgical procedure (medical history), and indications to the surgical procedure itself (failure of NSRCT or ReTx, presence of radiographic or clinical apical periodontitis etc...) constituted selection criteria. Hence, our patients represent no exception to patients presenting into any other dental care center for

EMS.

Future Research Directions

Future research is necessary in order to offer the best therapeutic option for our patients. Concerning EMS, future research should be done on a larger scale and on longer follow-up periods in order to compare the clinical performance of MTA and ERRM and to further investigate prognostic factors. Moreover, three-dimensional evaluation criteria should be revisited and correlated with histologic findings.

Conclusion

Based on this RCT, using MTA or ERRM as a retro-filling material does not influence outcome of EMS whether assessed on PA or CBCT. EMS is a predictable procedure with high success rate. However, outcome was significantly better for teeth with pre-operative cortical buccal plate, with pre-operative microsurgical classification A or B, with lesion diameter $\leq 5\text{mm}$, with adequate root canal filling quality, with adequate retro-fill depth and alignment and for teeth without root fractures.

References

1. Karabucak B, Setzer F. Criteria for the ideal treatment option for failed endodontics: surgical or nonsurgical? *Compend Contin Educ Dent*. 2007;28:391-7
2. Gorni FG, Gagliani MM. The outcome of endodontic retreatment: a 2-yr follow-up. *J Endod*. 2004;30:1-4.
3. Walton RE, Ardjmand K. Histological evaluation of the presence of bacteria in induced periapical lesions in monkeys. *J Endod*. 1992;18:216-27.
4. Siqueira JF Jr, Lopes HP. Bacteria on the apical root surfaces of untreated teeth with periradicular lesions: a scanning electron microscopy study. *Int Endod J*. 2001;34:216-20.

5. Tronstad L, Barnett F, Cervone F. Periapical bacterial plaque in teeth refractory to endodontic treatment. *Endod Dent Traumatol.*
6. Ramachandran Nair PN. Light and electron microscopic studies of root canal flora and periapical lesions. *J Endod.* 1987;13:29-39.
7. Sunde PT, Olsen I, Göbel UB, Theegarten D, Winter S, Debelian GJ, Tronstad L, Moter A. Fluorescence in situ hybridization (FISH) for direct visualization of bacteria in periapical lesions of asymptomatic root-filled teeth. *Microbiology.* 2003;149:1095-102.
8. Sjögren U, Happonen RP, Kahnberg KE, Sundqvist G. Survival of *Arachnia propionica* in periapical tissue. *Int Endod J.* 1988;21:277-82.
9. Ricucci D, Siqueira JF Jr. Apical actinomycosis as a continuum of intraradicular and extraradicular infection: case report and critical review on its involvement with treatment failure. *J Endod.* 2008;34:1124-9.
10. Friedman S. The prognosis and expected outcome of apical surgery. *Endod Topics* 2005;11:219-262
11. Dorn SO, Gartner AH. Surgical endodontic and retrograde procedures. *Curr Opin Dent.* 1991;1:750-3.
12. Harty FJ, Parkins BJ, Wengraf AM. The success rate of apicectomy. A retrospective study of 1,016 cases. *Br Dent J.* 1970;129:407-13.
13. Oginni AO, Olusile AO. Follow-up study of apicectomised anterior teeth. *SADJ.* 2002;57:136-40.
14. Tsesis I, Faivishevsky V, Kfir A, Rosen E. Outcome of surgical endodontic treatment performed by a modern technique: a meta-analysis of literature. *J Endod.* 2009;35:1505-11.
15. Kim S, Kratchman S. Modern endodontic surgery concepts and practice: a review. *J Endod* 2006;32:60123.
16. Setzer FC, Shah S, Kohli M, Karabucak B, Kim S. Outcome Of Endodontic Surgery: A Meta-Analysis Of The Literature - Part 1: Comparison Of Traditional Root- End Surgery And Endodontic Microsurgery. *J Endod.* 2010;36:1757-1765
17. Setzer FC, Kohli M, Shah S, Karabucak B, Kim S. Outcome of Endodontic Surgery: A Meta-analysis of the Literature - Part 2: Comparison of Endodontic Microsurgical Techniques With and Without the Use of Higher Magnification. *J Endod.* 2012;38:1-10

18. Baek SH, Plenk H, Kim S. Periapical tissue responses and cementum regeneration with amalgam, SuperEBA, and MTA as root-end filling materials. *J Endod* 2005;31: 4449.
19. Dorn SO, Gartner AH. Retrograde filling materials: A retrospective success-failure study of amalgam, EBA and IRM. *J Endod* 1990;16:3913.
20. Oynick J, Oynick T. A study of a new material for retrograde fillings. *J Endod* 1978;4: 2036.
21. Trope M, Lost C, Schmitz HJ, et al. Healing of apical periodontitis in dogs after apicoectomy and retrofilling with various filling materials. *Oral Surg Oral Med Oral Pathol* 1996;81:2218.
22. Pitt Ford TR, Andreasen JO, Dorn SO, et al. Effect of SuperEBA as a root-end filling on healing after replantation. *J Endod* 1995;21:135.
23. Torabinejad M, Hong CU, PittFord TR, et al. Tissue reaction to implanted Super-EBA and mineral trioxide aggregate in the mandible of guinea pigs: a preliminary report. *J Endod* 1995;21:56971.
24. Torabinejad M, Watson TF, Pitt Ford TR. The sealing ability of a mineral trioxide aggregate as a root end filling material. *J Endod* 1993;19:5915.
25. Camilleri J, The chemical composition of mineral trioxide aggregate. *J Conserv Dent* 2008;11:1411-43.
26. Torabinejad M, Smith PW, Kettering JD, et al. Comparative investigation of marginal adaptation of mineral trioxide aggregate and other commonly used rootend filling materials. *J Endod* 1995;21:2959.
27. Keiser K, Johnson C, Tipton D. Cytotoxicity of mineral trioxide aggregated using human periodontal ligament fibroblasts. *J Endod* 2000;26:28891.
28. Torabinejad M, Hong CU, McDonald F, et al. Physical and chemical properties of a new root end filling material. *J Endod* 1995;21:34953.
29. Torabinejad M, Higa RK, McKendry DJ, et al. Dye leakage of four root end filling materials: effects of blood contamination. *J Endod* 1994;20:15963.
30. Torabinejad M, Rastegar AF, Kettering JD, et al. Bacterial leakage of mineraltrioxide aggregate as a root-end filling material. *J Endod* 1995;21:10912.
31. Bates CF, Carnes DL, del Rio CE. Longitudinal sealing ability of mineral trioxide aggregate as a root-end filling material. *J Endod* 1996;22:5758.
32. Koh ET, McDonald F, Pitt-Ford TR, et al. Cellular response to mineral trioxide

aggregate. J Endod 1998;24:5437.

33. Torabinejad M, Pitt- Ford TR, Abedi HR, et al. Tissue reaction to implanted root-end filling materials in the tibia and mandible of guinea pigs. J Endod 1998;24:46871.
34. Torabinejad M, Hong CU ,LeeSJ , et al. Investigation of mineral trioxide aggregate for root-end filling in dogs. J Endod 1995;21:6038.
35. Torabinejad M, Pitt Ford TR, McKendry D, et al. Histologic assessment of mineral trioxide aggregate as a root-end filling in monkeys. J Endod 1997;23:2258.
36. Baek SH, Lee WC, Setzer FC, Kim S. Periapical bone regeneration after endodontic microsurgery with three different root-end filling materials: amalgam, SuperEBA, and mineral trioxide aggregate. J Endod. 2010;36:1323-5.
37. Porter ML, Bertó A, Primus CM, Watanabe I. Physical and chemical properties of new-generation endodontic materials. J Endod. 2010;36:524-8.
38. Ber BS, Hatton JF, Stewart GP. Chemical modification of proroot mta to improve handling characteristics and decrease setting time. J Endod. 2007;33:1231-4.
39. Islam I, Chng HK, Yap AU. Comparison of the physical and mechanical properties of MTA and Portland cement. J Endod 2006;32:1937.
40. Torabinejad M, Hong CU, McDonald F, Pitt Ford TR. Physical and chemical properties of a new root-end filling material. J Endod 1995;21:34953.
41. Available at: <http://www.brasselerusa.com/brass/index.cfm/newproducts/>
42. AlAnezi AZ, Jiang J, Safavi KE, Spangberg LS, Zhu Q. Cytotoxicity evaluation of endo- sequence root repair material. Oral Surg Oral Med Oral Pathol Oral Radiol Endod 2010;109:e1225.
43. Damas BA, Wheeler MA, Bringas JS, Hoen MM. Cytotoxicity comparison of mineral trioxide aggregates and EndoSequence bioceramic root repair materials. J Endod 2011;37:3725.
44. Ma J, Shen Y, Stojicic S, Haapasalo M. Biocompatibility of two novel root repair materials. J Endod. 2011;37:793-8.
45. Zhang W, Li Z, Peng B. Assessment of a new root canal sealers apical sealing ability. Oral Surg Oral Med Oral Pathol Oral Radiol Endod 2009;107:e7982.
46. Zhang W, Li Z, Peng B. ex vivo cytotoxicity of a new calcium silicate-based canal filling material. Int Endod J 2010;43:76974.

47. Zhang H, Shen Y, Ruse ND, Haapasalo M. Antibacterial activity of endodontic sealers by modified direct contact test against *Enterococcus faecalis*. *J Endod* 2009;35:10515.
48. Lovato KF, Sedgley CM. Antibacterial activity of endosequence root repair material and proroot MTA against clinical isolates of *Enterococcus faecalis*. *J Endod*. 2011;37:1542-6.
49. Laurent P, Camps J, De Méo M, Déjou J, About I. Induction of specific cell responses to a Ca(3)SiO(5)-based posterior restorative material. *Dent Mater*. 2008;24:1486-94.
50. Goldberg M, Pradelle-Plasse N, Tran X et al. Emerging trends in (bio)material researches. In: Goldberg M, ed. *Biocompatibility or cytotoxic effects of dental composites*. Coxmoor Publishing, Oxford, UK, 2009:181203.
51. Han L, Okiji T. Uptake of calcium and silicon released from calcium silicate-based endodontic materials into root canal dentine. *Int Endod J*. 2011;44:1081-7.
52. Mead C, Javidan- Nejad S, Mego ME, Nash B, Torabinejad M. Levels of evidence for the outcome of endodontic surgery. *J Endod* 2005;31:1924.
53. Chugal N, Clive J, Spånberg L. Endodontic infection: some biologic and treatment factors associated with outcome. *Oral Surg, Oral Med, Oral Path, Oral Rad, and Endo* 2003; 96: 81-90.
54. Sjogren U, Hagglund B, Sundqvist G, Wing K. Factors affecting the long-term results of endodontic treatment. *J Endod*. 1990;16:498-504.
55. Rud J, Andreasen JO, Moller Jensen JE. A multivariate: analysis of the influence of various factors upon healing after endodontic surgery. *Int J Oral Surg*. 1972; 251-78.
56. Molven O, Halse A, Grung B. Observer strategy and the radiographic classification of healing after endodontic surgery. *Int J Oral Maxillofac Surg* 1987;16:4329.
57. Chen I, Karabucak B, Wang C, Wang HG, Koyama E, Kohli MR, Nah HD, Kim S. Healing after root-end microsurgery by using mineral trioxide aggregate and a new calcium silicate-based bioceramic material as root-end filling materials in dogs. *J Endod*. 2015 41:389-99.

Annex

Table 1: Surgical evaluation form.

Patient Information

Chart #: _____
Gender: _____

Tooth / Root: _____

Pre-Surgical Evaluation

Tooth/Root	Percussion	Palpation	Sinus Tract	Probing	Broken instrument	ReTx

Initial Pulpal Diagnosis: _____

Apical Diagnosis: _____

Date of EMS completion: ____/____/____

Tooth Position and jaw: _____

Date of follow-up visit: ____/____/____

Microsurgical Classification: _____

Root canal filling quality: _____

Root canal filling Length: _____

Cortical Plate: _____

Lesion size: _____

Post-Surgical Evaluation

Tooth/Root	Percussion	Palpation	Sinus Tract	Probing	Filling	Fracture

Alignment: _____

Depth: _____

Missed Canal(s): _____

Bridge abutment: _____

Interproximal contacts: _____

Membrane grafting: _____

Type of coronal restoration: _____

PA score: _____

CBCT score: _____

Table 2a: Scoring criteria used for potential pre-operative prognostic factors.

Parameter	Score	Criteria
Gender	1	Man
	2	Woman
Signs and symptoms	0	Absence
	1	Presence
Broken instrument	0	No
	1	Yes
ReTx	0	No
	1	Yes
Initial pulpal diagnosis	1	Symptomatic Irreversible Pulpitis
	2	Pulp Necrosis
	3	Previously Treated
	4	Asymptomatic Irreversible Pulpitis
Apical Diagnosis	1	Symptomatic Apical Periodontitis
	2	Asymptomatic Apical Periodontitis
	3	Chronical Apical Abscess
Tooth Position	1	Anterior (Incisors, canines, premolars)
	2	Posterior (molars)
Jaw	1	Maxilla
	2	Mandible
Microsurgical Classification	1	A
	2	B
	3	C
Root Canal filling Quality	0	Inadequate
	1	Adequate
Root Canal filling Length	0	Inadequate
	1	Adequate
Cortical	0	Absent
	1	Present
Lesion size	1	≤ 5mm
	2	>5mm

Table 2b: Scoring criteria used for potential post-operative prognostic factors.

Parameter	Score	Criteria
Signs and symptoms	0	Absence
	1	Presence
Fracture	0	Absence
	1	Presence
Alignment	0	Inadequate
	1	Adequate
Depth	1	Inadequate
	2	Adequate
Missed canal	0	Absence
	1	Presence
Bridge abutment	0	No
	1	Yes
Interproximal contacts	0	Absent
	1	Present
Collagen based membrane graft	1	Used
	2	Not used
Type of coronal restoration	1	Adequate full coverage
	2	Inadequate full coverage
	3	Adequate bonded restoration
	4	Inadequate bonded restoration

Table 3: Criteria for evaluating EMS on PA according to Rud et al and Molven et al

Complete Healing *

- (1) Re-formation of periodontal space of normal width and lamina dura to be followed around the apex (Fig 1A)
- (2) Slight increase in width of apical periodontal space, but less than twice the width of non-involved parts of the root (Fig 1B).
- (3) Tiny defect in the lamina dura (maximum 1 mm ~) adjacent to the root filling (Fig 1C)
- (4) Complete bone repair; bone bordering the apical area does not have the same density as surrounding non-involved bone (Fig 1D).
- (5) Complete bone repair; no apical periodontal space can be discerned (Fig 1E)

Incomplete Healing/Scar *

The rarefaction has decreased in size or remained stationary, and is characterized by:

- (1) Bone structures are recognized within the rarefaction; the periphery of the rarefaction is irregular and may be demarcated by a compact bone border; the rarefaction is located asymmetrically around the apex; the connection of the rarefaction with the periodontal space is angular (Fig 1F).
- (2) Isolated scar tissue in the bone with findings also shown in (1).

Uncertain Healing**

The rarefaction has decreased in size, and with one or more of the following characteristics:

- (1) The RL is larger than twice the width of the periodontal space (Fig 1G)
- (2) The RL is bordered by lamina-dura like bone structures
- (3) The RL has a circular or semicircular periphery (Fig 1H)
- (4) The RL is located symmetrically around the apex as a funnel-shaped extension of the periodontal space

Unsatisfactory Healing**

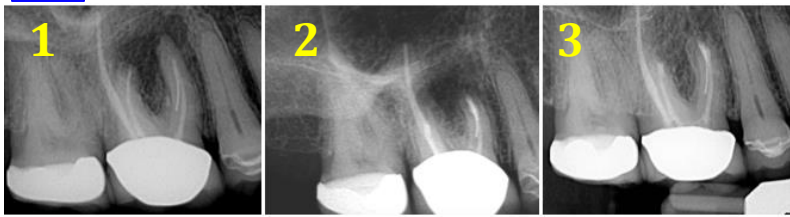
The RL area appears enlarged or unchanged (Fig 1I)

* Complete and incomplete/scar categories were combined as success (Score of 1)

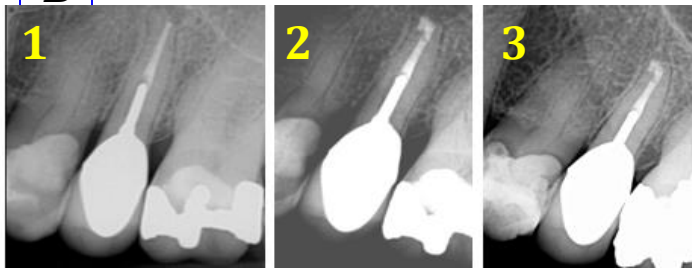
** Uncertain and unsatisfactory healing were combined as failure (Score of 2)

Figure1: Representative PA of some outcome category. Legend next 2 pages.

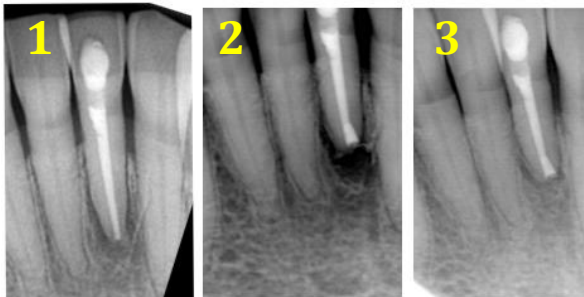A



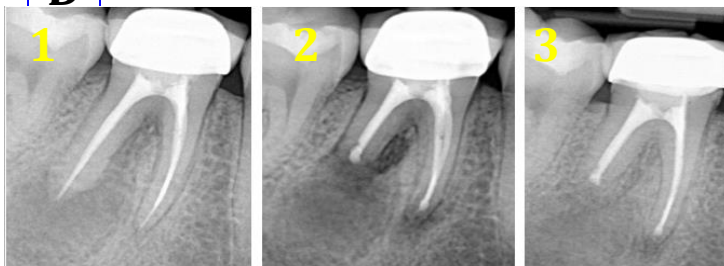B



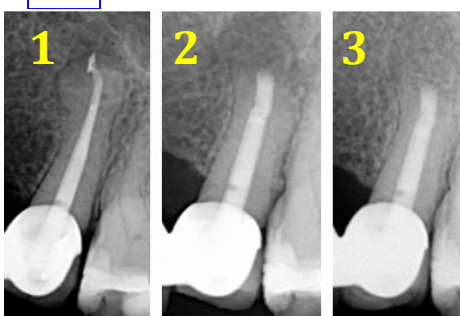
C



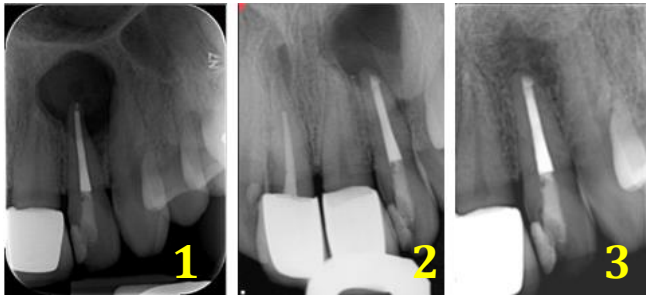
D



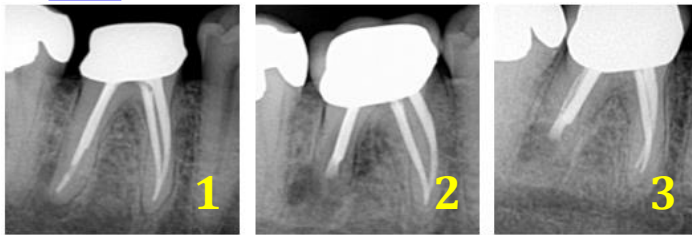
E



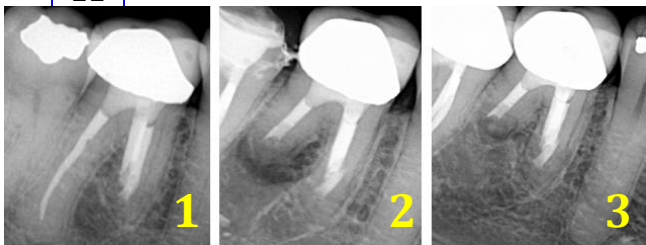
F



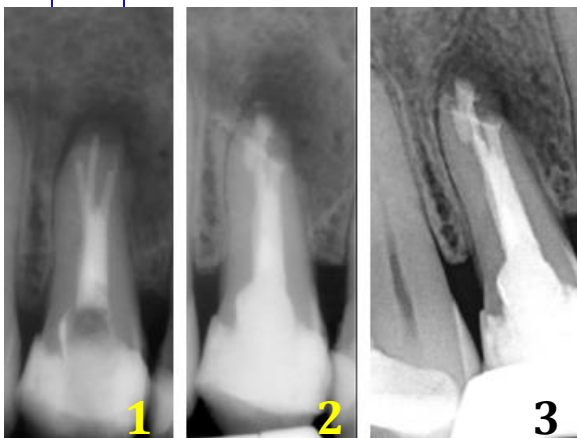G



H



I



In all panels, 1 is pre-operative PA, 2 is post-operative PA, and 3 is follow-up PA.

A= Mesial and distal root of tooth #3 showing complete healing. ERRM was used. Normal periodontal space and lamina dura reformed on both roots.

B= Single-rooted #13 showing complete healing. ERRM was used. A slight increase in width of the apical periodontal space was observed..

C= Tooth #23 showing complete healing. MTA was used. Lamina dura shows defect around root filling.

D= Mesial root of tooth #30 showing complete healing. The apical area does not have the same density as the surrounding bone. The distal root shows complete healing as well but is not under the same subcategory as the mesial root. MTA was used.

E= Tooth #13 showing complete healing. ERRM was used. No apical periodontal space was discerned.

F= Tooth #10 showing incomplete healing/ scar. ERRM was used.

G= Tooth #30 showing uncertain healing around the distal root. ERRM was used. The radiolucency was larger than twice the width of the periodontal space.

H= Tooth #30 showing uncertain healing around the distal root. The radiolucency has a circular periphery. The mesial root was not part of the study. MTA was used.

I= Unsatisfactory healing of tooth # 5. The radiolucent area appears unchanged. ERRM was used.

Table 4: Penn Criteria for evaluating EMS on CBCT

Complete Healing *

- (1) Re-formation of periodontal space of normal width and lamina dura over the entire resected and un-resected root surfaces (Fig 2A)
- (2) Slight increase in width of apical periodontal space over the resected root surface, but less than twice the width of non-involved parts of the root.
- (3) Small defect in the lamina dura surrounding the root-end filling. (Fig 2B)
- (4) Complete bone repair with discernible lamina dura; bone bordering the apical area does not have the same density as surrounding non-involved bone.
- (5) Complete bone repair. Hard tissue covering the resected root-end surface completely. No apical periodontal space can be discerned. (Fig 2C)

Limited Healing *

Complete healing can be observed in immediate vicinity of the resected root surface, but the site demonstrates one of the following conditions:

- (1) The continuity of the cortical plate is interrupted by an area of lower density. (Fig 2D).
- (2) A low density area remains asymmetrically located around the apex or has an angular connection with the periodontal space (Fig 2E).
- (3) Bone has not fully formed in the area of the former access osteotomy (Fig 2F).
- (4) The cortical plate is healed but bone has not fully formed in the site (Fig 2G).

Unsatisfactory Healing **

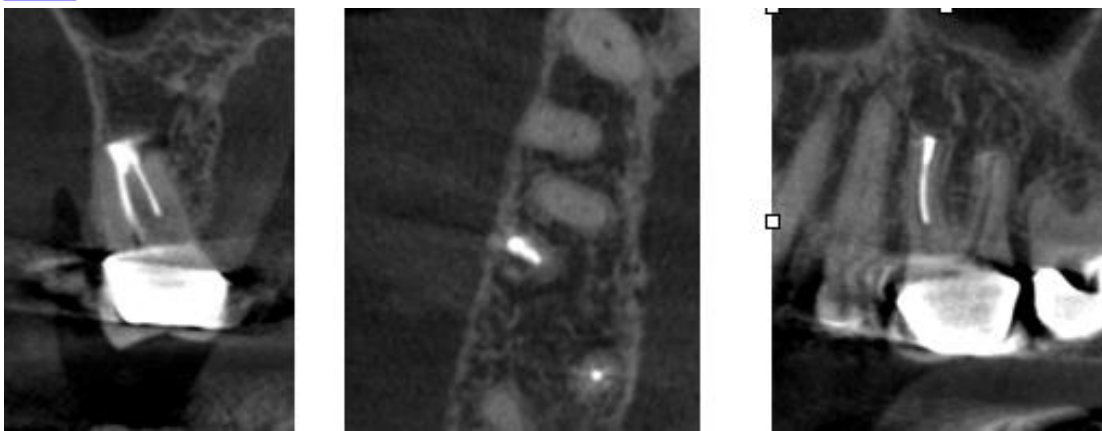
The volume of the low density area appears enlarged or unchanged (Fig 2H).

* Complete and limited categories were combined as success (Score of 1)

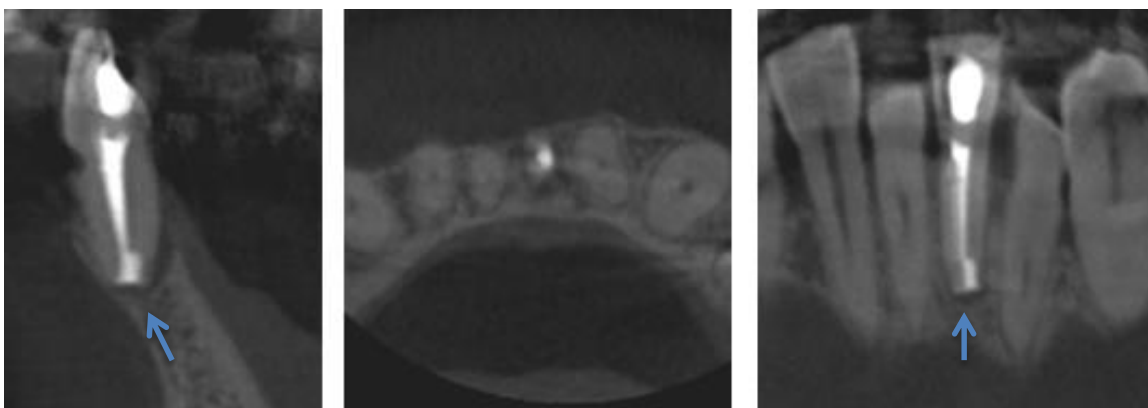
** Unsatisfactory cases received a score of 2

Figure 2: Representative CBCT of some outcome category. Legend next 2 pages.

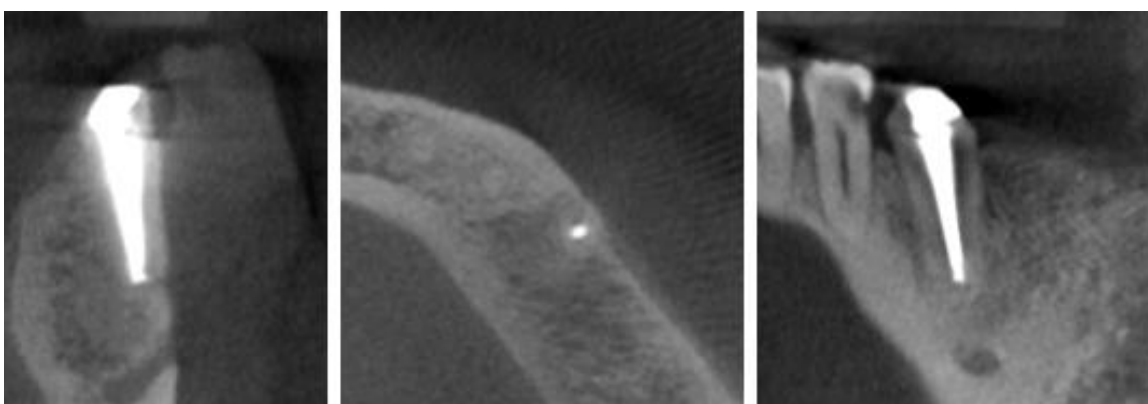
A



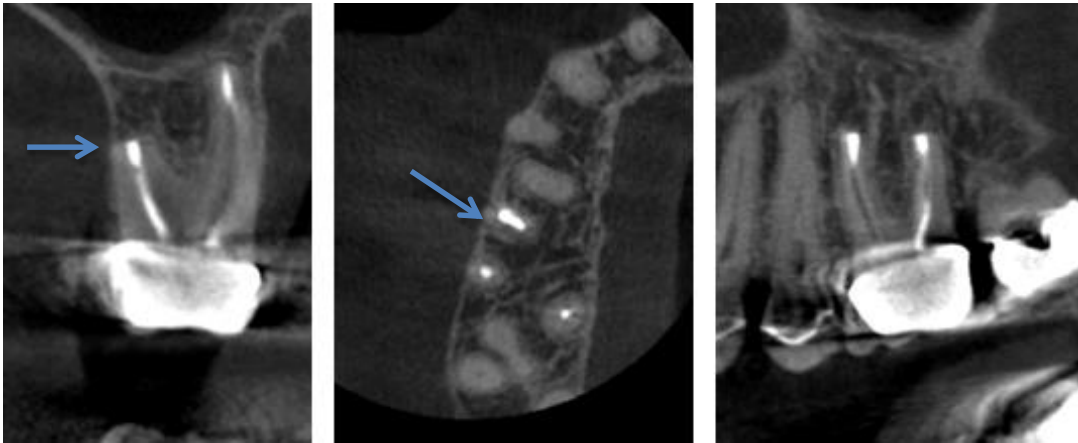
B



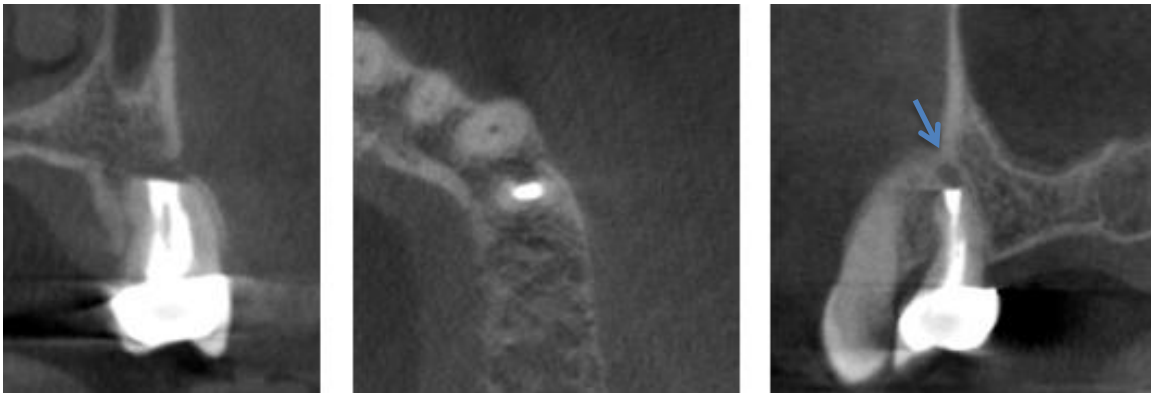
C



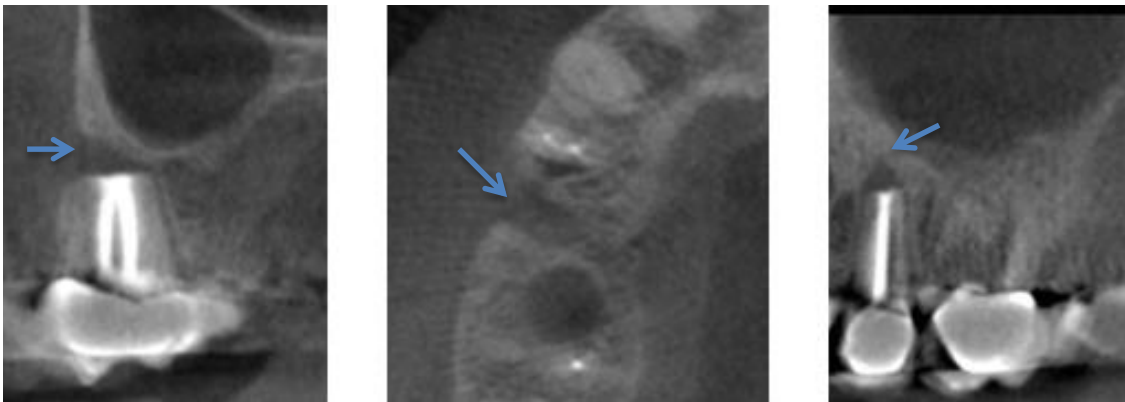
D



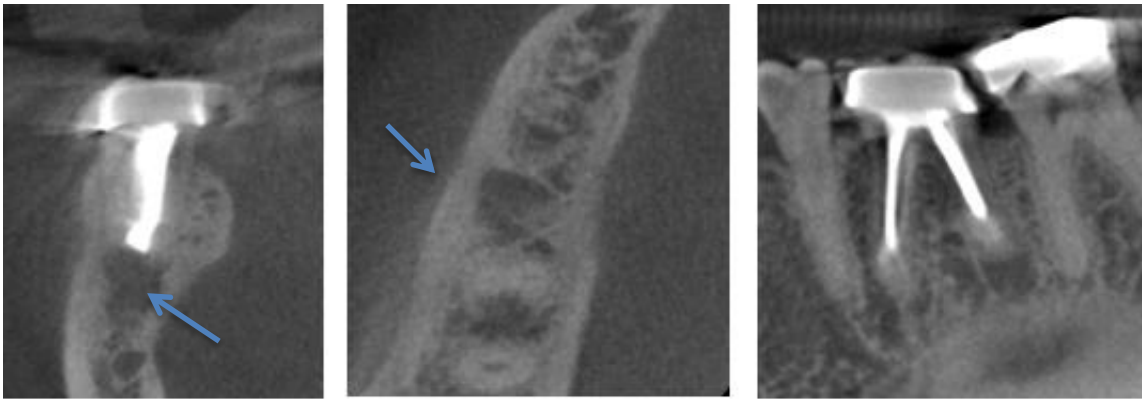
E



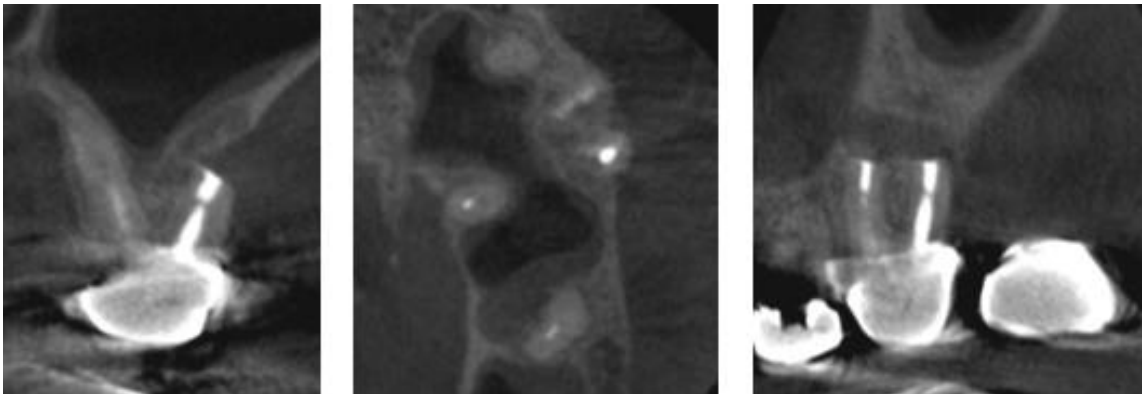
F



G



H



All panels represent follow-up CBCT. Left image is sagittal view, middle image is axial view, right image is coronal view.

A= Mesial root of tooth #3 showing complete healing. ERRM was used. Normal periodontal space and lamina dura reformed.

B= Tooth #23 showing complete healing. MTA was used. A slight increase in width of the apical periodontal space (blue arrows) was observed. C= Tooth #20 showing complete healing. MTA was used. No apical periodontal space was discerned.

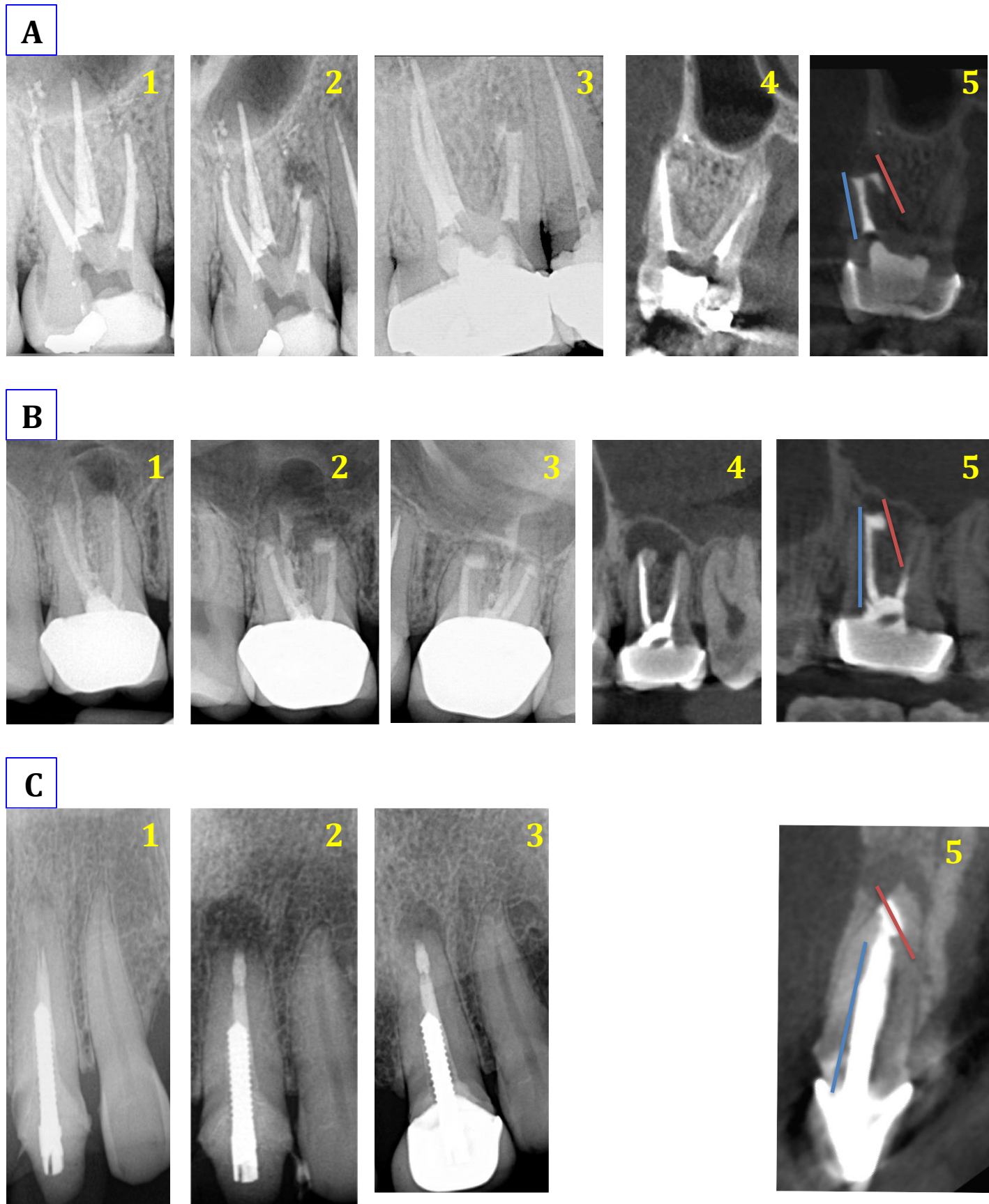
D= Distal root of tooth #3 showing limited healing. ERRM was used. Cortical plate is interrupted (blue arrow). E= Tooth #13 showing limited healing. MTA was used. A low density area (blue arrow) is seen around the apex.

F= Tooth #5 showing limited healing. MTA was used. Bone not formed in area of access osteotomy (blue arrow).

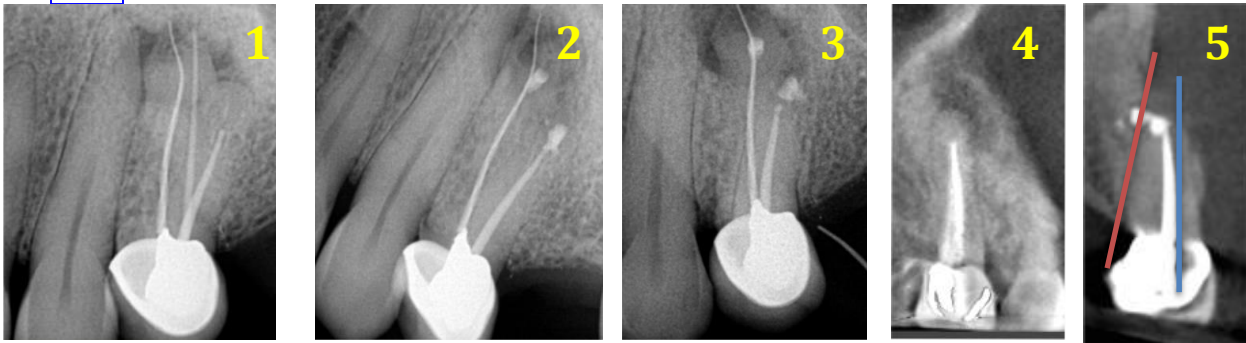
G= Tooth #19 showing limited healing around the distal root. ERRM was used.

Complete healing of the cortical is seen but not of cancellous bone. H= Distal root of tooth #14 showing unsatisfactory healing.

Figure 3a: Cases with procedural errors where the retro-filling material was not aligned with the long-axis of the root as seen on CBCT. See next page for legend.



D



In all panels, 1 is pre-operative PA, 2 is post-operative PA, 3 is follow-up PA, 4 is pre-operative CBCT, and 5 is follow-up CBCT. Blue line= root long axis. Red line= long axis of retro-filling.

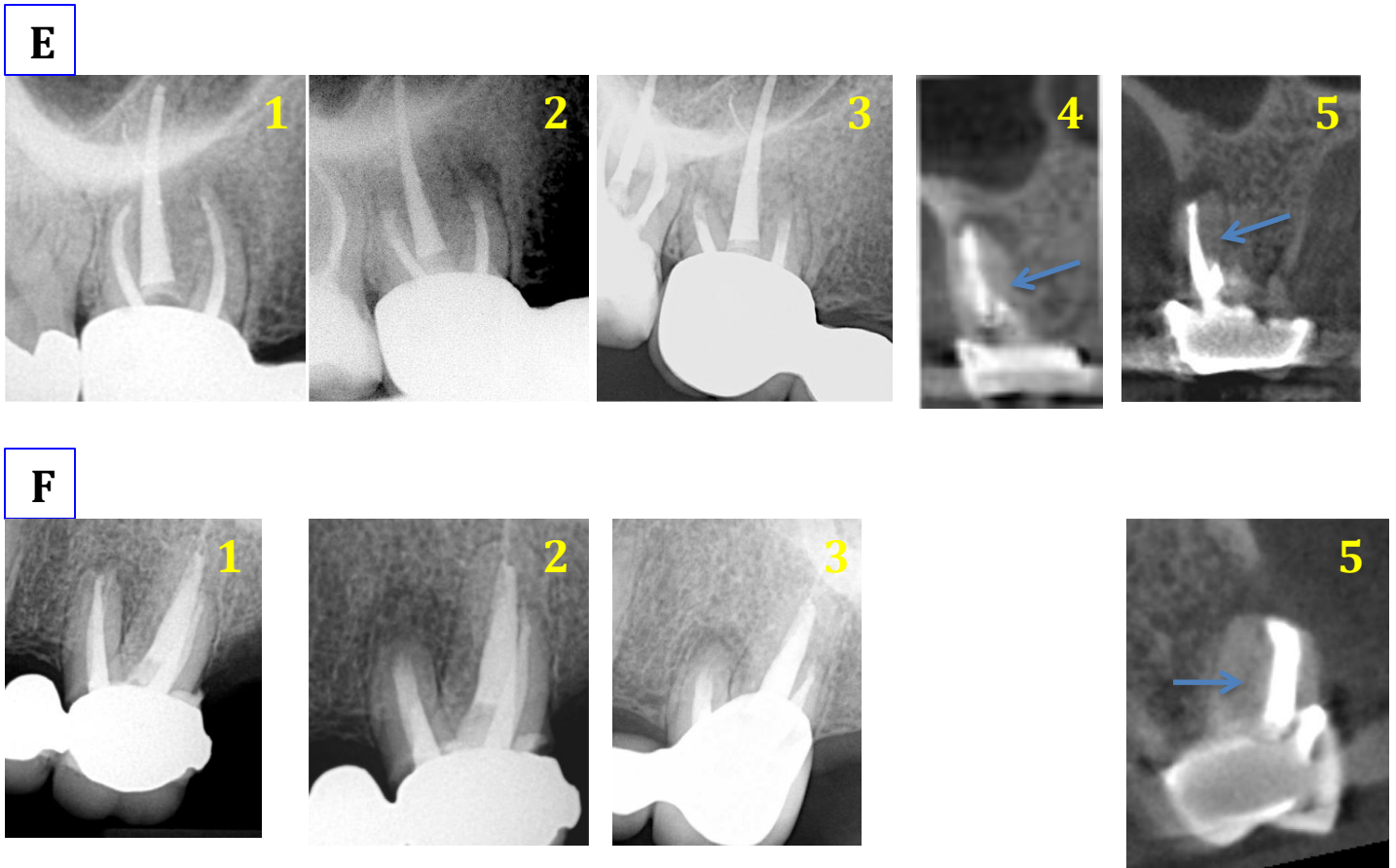
A= Procedural error on mesial root of tooth #3: Retro-filling was misaligned and was outside the root canal walls. MTA was used. Follow-up at 6 months showed complete healing on PA and CBCT.

B= Procedural error on mesial root of tooth #3: Retro-filling was misaligned and was outside the root canal walls. MTA was used. Follow-up at 15 months showed complete healing on PA and CBCT.

C= Procedural error on tooth #9: Retro-filling was misaligned ERRM was used. Follow-up at 24 months showed uncertain healing on PA and CBCT. Pre-Op CBCT Not available.

D= Procedural error on tooth buccal root on tooth #12: Retro-filling was misaligned and was outside the root canal walls ERRM was used. Follow-up at 24 months showed uncertain healing on PA and CBCT.

Figure 3b: Cases with procedural errors where a missed canal was neither retro prepared nor retro-filled as seen on CBCT. See bottom page for legend.



In all panels, 1 is pre-operative PA, 2 is post-operative PA, 3 is follow-up PA, 4 is pre-operative CBCT, and 5 is follow-up CBCT. Arrow points at missed canal.

E= Procedural error on mesial root of tooth #3: a missed second mesio-buccal canal was not retro-prepared nor retro-filled. ERRM was used on the first mesio-buccal canal. Follow-up at 12 months showed complete healing on PA but uncertain healing on CBCT.

F= Procedural error on mesial root of tooth #14: a missed second mesio-buccal canal was not retro-prepared nor retro-filled. ERRM was used on the first mesio-buccal canal. Follow-up at 12 months showed uncertain healing on PA and on CBCT. Pre-Op CBCT not available.

Figure 4a: Distribution of success according to PA and CBCT for group A

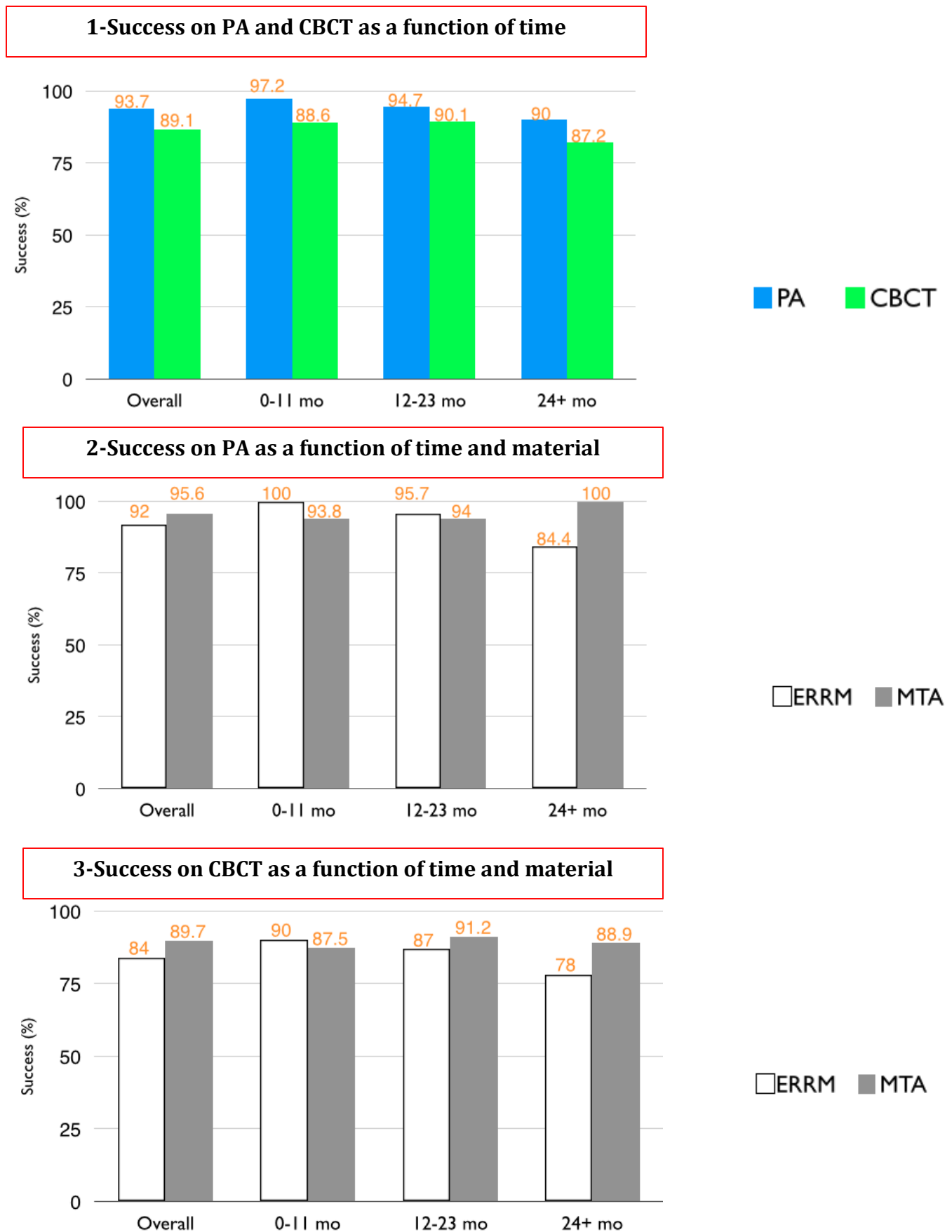


Figure 4b: Distribution of success according to PA and CBCT for group B

