

A New Technique to Diagnose Hip Dysplasia

Hip dysplasia in dogs was first described in 1935 by Dr. G. B. Schnelle of the Angell Memorial Hospital. Since then, much research has been done to determine the causes of the disease and to develop diagnostic techniques. It has been shown that hip dysplasia is a polygenic trait; about 30 percent of the disease is attributable to inheritance; environmental factors such as nutrition, exercise, and injury also play a part in the development of the disease. In dogs, hip dysplasia primarily affects large and giant breeds. It also occurs in chickens, pigs, horses, and cows.

Hip dysplasia, an instability of the hip joint, causes osteoarthritis in the joint. This can be a painful, and in some cases a severely crippling condition. Affected dogs often have limited stamina and can not fulfill their functions as working, herding, and hunting dogs. Currently the disease is diagnosed through radiography. About 70 percent of the affected individuals can be identified by this method at age one year. By the age of two years 92 to 95 percent of the affected dogs can be identified. It has been shown that the incidence of hip dysplasia in a breed can be reduced if only breeding stock is utilized which has radiographically normal hips. To that end a voluntary screening program is available through the Orthopedic Foundation for Animals.

The late diagnosis of the disease creates a problem for breeders, trainers, and pet owners. By the time a dog is two years old, much time and money has been spent in training it for tasks such as sentry duty or guide dog. If the dog is a hunting dog, much effort has gone into field training. Also a bond has developed between the dog and the family. By two years of age many dogs of the affected breeds have already been used for breeding, particularly males. Thus it becomes important to develop a method of identifying dogs that may develop hip dysplasia at an earlier age than one or two years.

Dr. Gail Smith, assistant professor of orthopedics at the University of Pennsylvania School of Veterinary Medicine, is developing a diagnostic method which would allow early identification of affected animals. Dr. Smith, a veterinarian and a bioengineer, has been

looking at the hip joint not only from an anatomical point of view but also from a mechanical one. "The hip joint is the least constrained of all the joints in the body, and it has the largest range of motion. A ball and socket joint, it is held in place by the round ligament, the joint capsule, and muscle forces. In addition to these three elements, there is a fourth, previously overlooked factor, the synovial fluid. It acts as a joint lubricant and, together with the joint capsule, creates an anticavitational constraint to prevent coxofemoral subluxation," Dr. Smith feels that the synovial fluid plays a crucial role in the development of hip dysplasia. "Optimum performance of the joint is achieved when there is a fixed and minimal amount of fluid in the joint. The capsular/fluid dynamic phenomena can be negated by adding a small amount of fluid to the joint capsule; this will result in marked coxofemoral laxity."

According to Dr. Smith, hip dysplasia could be indirectly the result of aberration in synovial fluid volume rather than lack of soft tissue constraints. New potential etiological factors for hip dysplasia could include those mechanisms known to affect synovial fluid volume such as joint effusion secondary to trauma, autoimmune phenomena, infection, or metabolic aberrations. Studies are needed to determine these factors and their role in the development of the disease.

"For the past two years we have been examining litters of German shepherds radiographically," Dr. Smith said. "We do not use the traditional positioning method with the dog on its back and the rear legs extended parallel. Rather, we put the legs into a flexed position and apply a small compressive force to seat the femoral head into the acetabulum. This is the normal stance, and it shows the joint in a natural position with the round ligament and the joint capsule relaxed (Fig. 1). This technique provides a good view of the joint. The second radiograph is taken with the dog in the same flexed position, but this time lateral force is exerted to pull the joint apart slightly." If the normal amount of synovial fluid is present, its volume and the surrounding joint capsule act together to create a vacuum-like effect, preventing the socket from slipping out of the joint (Fig. 2). If there is excess fluid, the joint capsule will be stretched, the anticavitational constraint will not be present, and the joint will subluxate (Fig. 3). Dr. Smith contends that

the traditional positioning method actually slightly twists and thus tightens the joint capsule, resulting in some cases in false negative status of the hip joints (Fig. 4). "When you look at some dogs, which by the traditional method show no subluxation, with the new radiographic technique, you will find that subluxation does exist."

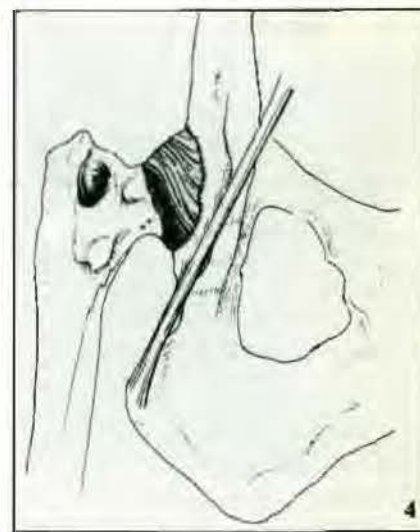
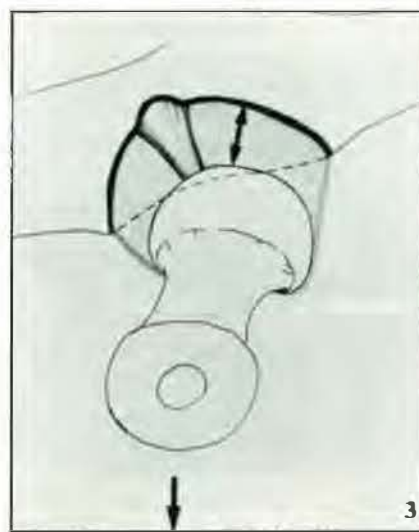
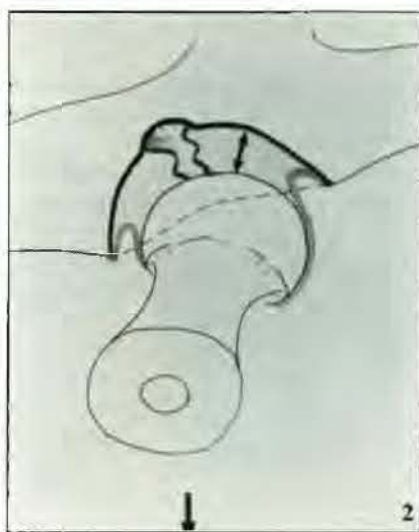
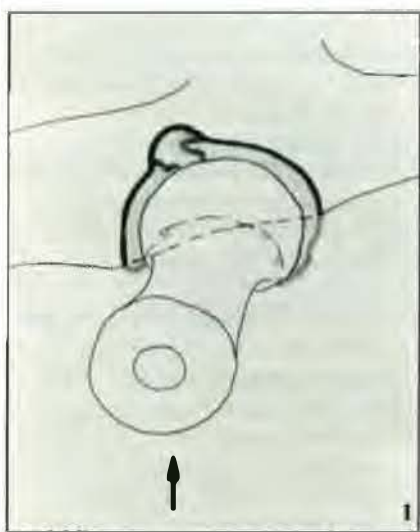
Dr. Smith and his colleagues have developed a formula by which they calculate the degree of subluxation. "We can now look at the radiographs of 16-week-old puppies and detect whether the subluxation caused by the lateral force is normal or abnormal. If it is the latter, we expect the dog to develop dysplasia." Dr. Smith and his colleagues have radiographed these puppies at a later age and as adults and have found that the dogs that had the normal amount of subluxation due to the lateral force developed normal hips. Dogs with greater subluxation became dysplastic.

"It appears that by using this new technique we will be able to accurately predict which dogs will develop normal hips and which will not," he said. "We also think that this technique will be more accurate than the present one in detecting affected animals. By identifying affected animals at a young age, much time and money can be saved, as these dogs then will not be used as sentry, guide, or field trial dogs. Also, it allows breeders to evaluate a breeding program much earlier."

Dr. Smith is now developing an apparatus which will hold the dog in the flexed position and will exert a carefully calibrated lateral force. "We think it will be possible to design and build such a device which then can be used by veterinarians. It is important that the lateral force exerted is proper to prevent damage to the joint." He is also studying the biomechanics of the hip joint, and he hopes that a medical treatment can be developed eventually to prevent hip dysplasia once the subluxation has been detected. "Once we understand why some dogs have an excess amount of synovial fluid, perhaps steps can be taken to reduce it. But that is far in the future."

The research is supported by funds from the Morris Animal Foundation, The Seeing Eye Inc., and the University of Pennsylvania Research Fund. Dr. Darryl G. Biery is a coinvestigator on the grant and provides expertise in radiographic interpretation.

—H.W.



Refurbishing of the Isolation Barn

New Bolton Center's six-stall isolation barn is being refurbished through the generosity of the Cheever Porter Foundation. The garage door opening to the walkway between the barns is gone. In its stead is a regular door. The floor is resurfaced, and new drains and waterlines have been installed. Each stall is equipped with a faucet, making in-stall hydrotherapy possible. Also added were stainless steel sinks in each of the stall anterooms. Sliding windows at each feeding area were installed to permit adding feed without entering the stall. This new feature also allows clinicians and nurses to better observe each patient. A pulley system for handling the 20 liter IV fluid bottles was added, enabling one person to handle the heavy

jugs. The common work area was improved. Now there is a counter with laboratory equipment for simple tests, a centrifuge, and a total solids meter. Also purchased and installed were a small refrigerator and a microwave oven.

New Bolton Center's isolation barn is much in use. "When horses with diarrhea are admitted, they are placed here," said Dr. Jonathan Palmer. "As salmonella is a common diagnosis for horses with diarrhea, we must make sure that a patient does not have it before being moved to a common barn." Cultures for salmonellosis are performed, and only after three negative cultures is the horse moved from the isolation barn."

As salmonella is quite contagious, special disinfection measures are taken for each stall that was occupied in the isolation unit. "The stall is thoroughly scrubbed, disinfected, and then cultures are taken over

a period of days. Once we have three negative ones, the stall can be used again." This results in a rather long turn-around time for each stall, but it is needed to protect each patient entering the unit.

A forced air ventilation system is also planned for the isolation barn. It will be installed at a later date. "With the renovations to date, the isolation barn is much better," said Dr. Palmer. "It has made it easier for the clinicians and nurses to work on the horses, and the new drainage system helps us to keep it even cleaner than before."

Scholarship Funds

The School has received \$50,000 from the Salisbury Foundation for the student scholarship fund. Contributions to this fund were also made by Dr. Carol A. Dolinskas, a client of VHUP.